



CASE REPORT

Paramedian forehead flap for nasal tip reconstruction after Mohs surgery

Felipe Bochnia Cerci

Hospital Santa Casa de Curitiba, Department of Dermatology, Curitiba, Paraná, Brazil

Abstract: The paramedian forehead flap is a great option for restoring complex nasal defects. Its main indications are large and deep wounds located on the distal third of the nose (tip and ala). For full-thickness defects, the paramedian forehead flap may be used alone or in combination with other methods. We presented a patient with a nodular basal cell carcinoma on the nasal tip and collumela treated by Mohs micrographic surgery and repaired with a paramedian forehead flap. Prior to reconstruction, it is essential that surgical margins are completely evaluated and free of tumor. For optimal paramedian forehead flap results, adequate surgical planning and meticulous technique are imperative.

Keywords: Mohs surgery; surgical flaps; nose neoplasms

Citation: Cerci FB. Paramedian forehead flap for nasal tip reconstruction after Mohs surgery. *J Surg Dermatol* 2019; 4(2): 16; <http://dx.doi.org/10.18282/jsd.v1.i1.16>.

*Correspondence to: Felipe Bochnia Cerci, Hospital Santa Casa de Curitiba, Department of Dermatology, Curitiba, Paraná, 80010-030, Brazil; cercihc@hotmail.com

Received: 27th March 2019; **Accepted:** 24th April 2019; **Published Online:** 17th May 2019

Introduction

The paramedian forehead flap (PFF) is a distinctive flap for the restoration of complex nasal defects. Its main indications are large and deep wounds located on the distal third of the nose (tip and ala), including full-thickness defects^[1,2]. The PFF can uniquely restore contour, texture and projection of the nasal tip and convexity of the ala, especially when combined with cartilage grafting. The disadvantages of this flap are the requirement of a multi-stage procedure and the forehead donor site scar, which is usually inconspicuous^[1,3]. Prior to reconstruction, surgical margins should be completely evaluated by Mohs micrographic surgery (if available) since a recurrence beneath a PFF would be catastrophic.

Case report

A 77-year-old woman presented to the Department of Dermatology with a 1.6 cm erythematous nodule involving the nasal tip and collumela. A biopsy was performed and revealed a nodular basal cell carcinoma. The patient

was submitted to Mohs micrographic surgery under local anesthesia (bupivacaine and lidocaine). After two stages, clear margins were achieved. The resulting defect measured 2.0 × 1.8 cm and affected the nasal tip and collumela (**Figure 1**). Parts of the lower lateral cartilages were removed. Due to the significant loss of volume of the nasal tip (**Figure 2**), a PFF was chosen to restore it. The main steps of the PFF are described below. For a more detailed description, several references are available^[1-3].

Initially, in order to restore nasal tip projection and for better flap support, a cartilage graft was harvested from the right auricular concha through a posterior incision and sutured with 4.0 vicryl on the nasal tip (**Figure 3**). After cartilage grafting, the PFF was designed based on the left supratrochlear artery demarcated on the supraorbital rim 1.5 cm lateral to the facial midline (**Figure 4**). The pedicle was designed with a 1.2 cm width. With a suture foil, a defect template was created and demarcated on the forehead, connected to the pedicle (**Figure 4**). The flap was then incised, elevated and sutured into the defect using 4.0 monocryl (subcutaneous/dermis) and 5.0

Copyright © 2019 Cerci FB. This is an Open Access article distributed under the terms of the Creative Commons Attribution-Non Commercial 4.0 International License (<http://creativecommons.org/licenses/by-nc/4.0/>), permitting all non-commercial use, distribution, and reproduction in any medium, provided the original work is properly cited.

nylon (dermis/epidermis). The forehead was closed primarily in three layers using 4.0 vicryl (galea/muscle/subcutaneous), 4.0 monocryl (subcutaneous/dermis) and 5.0 nylon (dermis/epidermis) (**Figure 5**).

After 4 weeks, the second stage was performed;

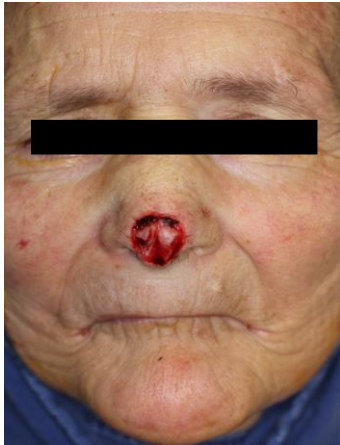

Figure 1. Surgical defect involving the nasal tip and collumela

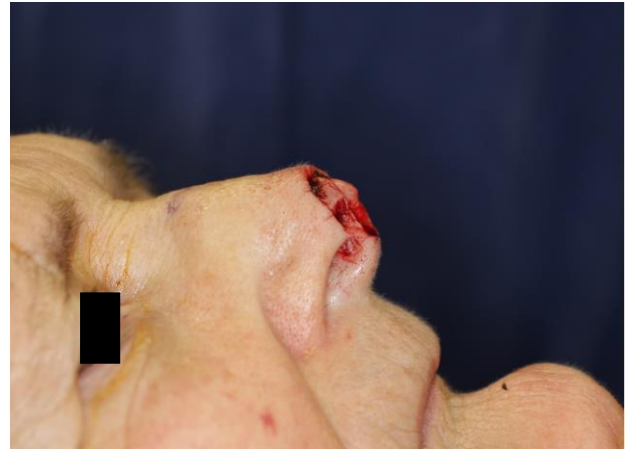

Figure 2. Important loss of volume of the nasal tip. Parts of the lower lateral cartilages were removed

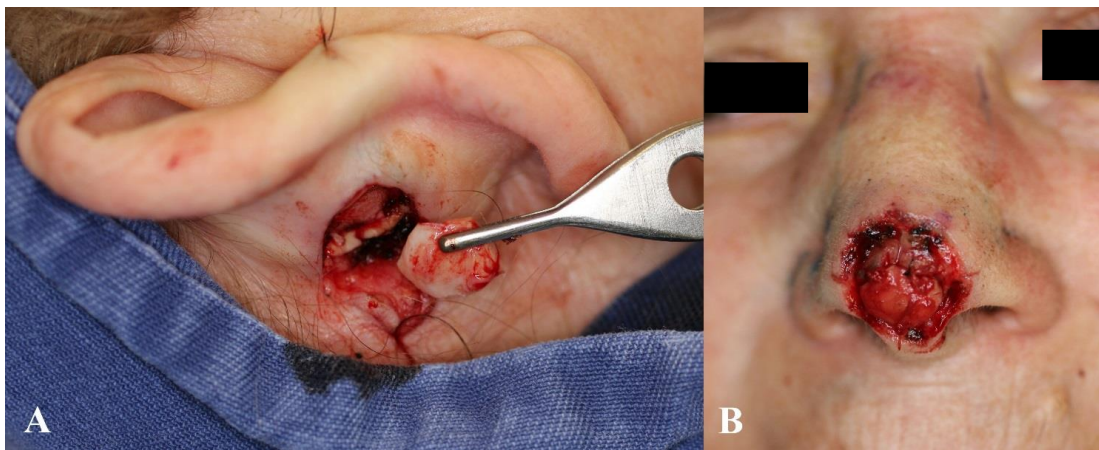


Figure 3. A) Conchal cartilage graft harvested through a posterior incision; B) Cartilage graft sutured on the nasal tip

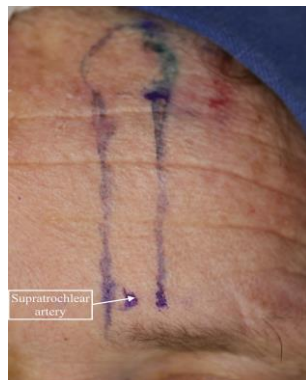

Figure 4. Paramedian forehead flap demarcated on the forehead. Pedicle based on the left supratrochlear artery

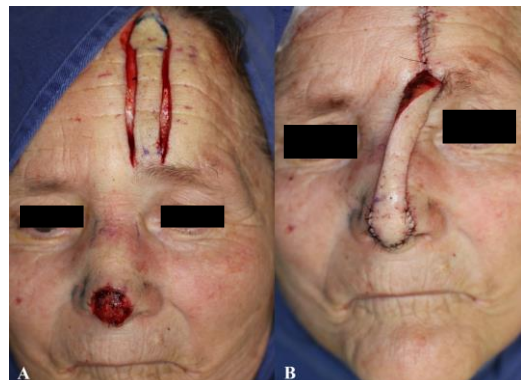


Figure 5. A) Flap incised; B) Flap sutured into place

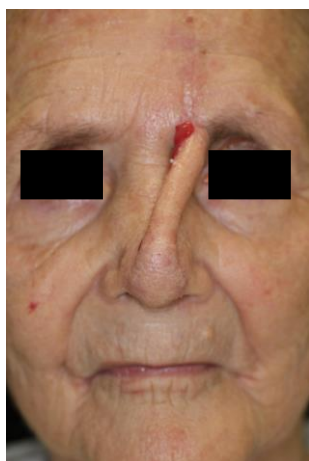

Figure 6. 4 weeks after the first stage

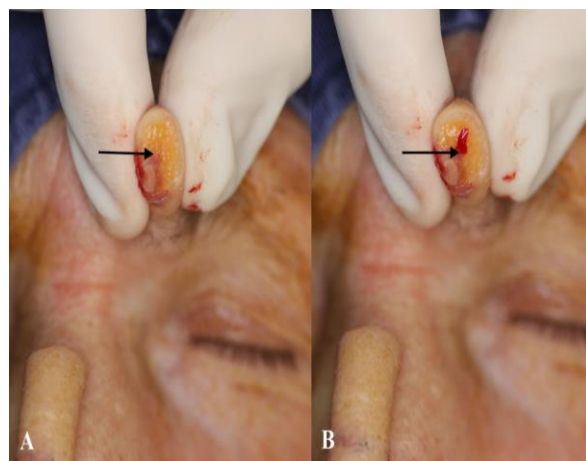

Figure 7. A) and B) Supratrochlear artery can be visualized after pedicle division (arrows)

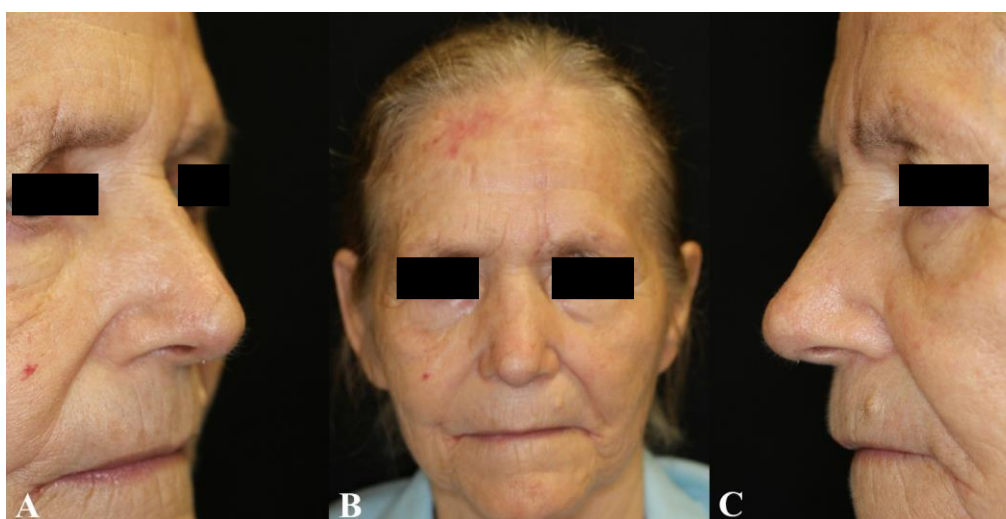

Figure 8. 5 weeks post-operatively. A) Oblique view; B) Frontal view (scar on the right forehead is from a different surgery); C) Lateral view. Note the adequate restoration of volume and projection of the nasal tip

Discussion

The nasal tip is a common location for the occurrence of non-melanoma skin cancer and frequently presents challenging surgical defects. When wounds are extensive, deep, and/or involve missing cartilage or mucosal lining, no other repair can approach the consistency and predictability of the PFF^[1]. For full-thickness defects, reconstruction should be performed in three layers: mucosal repair, cartilage grafting and soft tissue restoration.

The subunit principle is an essential concept in nasal reconstruction. When a defect involves more than 50%

of a subunit, one should consider excising the residual skin and resurfacing the entire subunit to achieve optimal aesthetic outcome^[4]. In the present case, cosmesis could have been further optimized by trimming the defect and recreating the supratip cosmetic junction.

The PFF can provide soft tissue covering but not structural support. Nasal lining and structural cartilage are infrastructures that must be either intact, supplemented and/or restored prior to the PFF^[4]. Several options are available to restore small mucosal defects (<1 cm) including a turnover hinge flap, turndown of a forehead flap extension, a full-thickness skin graft (FTSG), and bipedicle vestibular skin advancement flap. Larger

lining restoration may require a turnover forehead flap, FTSG vascularized by an overlying PFF, or intranasal lining flaps (septal mucoperichondrial hinge flap, composite septal chondromucosal pivotal flap)^[5,6]. Except for intranasal mucosal flaps, the other options mentioned may be successfully executed under local anesthesia^[1].

Cartilage grafts may be divided into two groups: structural (native cartilage present but require additional support) or restorative (replacing what was removed)^[1]. Structural functions of the cartilage include: preventing tissue contraction and distortion; bracing heavy flap tissue; maintaining airway patency and augmenting the internal nasal valve; and achieving contour support (i.e., nasal tip graft for better projection)^[2]. Donor sites for cartilage grafts may include the antihelix/scaphoid fossa and the conchal bowl^[7]. Antihelical cartilage is ideal for long, straight and flexible segments, whereas conchal cartilage is ideal for grafts that demand more curvature, substance and rigidity. Conchal grafts work better to avoid nasal valve or lobule collapse, and for collumela and tip projection. Antihelical cartilage is better suited to avoid alar rim contraction^[7-9].

The pedicle side is an important consideration when designing the PFF. Traditionally, the pedicle has been designed contralateral to the defect to minimize its torsion. However, a narrow pedicle (1 to 1.5 cm) allows an ipsilateral design without concerns of significant torsion^[3]. For defects located on the midline of the nose such as in the present case, either side of the pedicle is adequate. The flap should be elevated at three different planes. At the superior margin, it should be elevated in the superficial subcutaneous and gradually deepened into the deep subcutaneous and subgaleal plane as the dissection approaches the base of the pedicle in the eyebrow. At the inferior margin (at least 3 cm above the orbital rim), undermining must be subgaleal to avoid transection of the supratrochlear artery. The forehead is approximated as much as possible without tension. However, when significant tension is noted, the remaining wound should heal by second intention^[1,2]. The use of skin grafts for the remaining donor site closure can result in a large “patchy scar”. In the present case, due to the relative small size of the defect, the donor area could be entirely closed.

The safety of performing the PFF in an outpatient setting has been well documented, with low complication rates when performed with adequate technique^[10]. Potential complications of the PFF include bleeding, pain, poor scarring, infection, dehiscence, distortion of free margins and flap necrosis.

Conclusion

The PFF is a valuable flap in the repair of nasal tip defects following Mohs micrographic surgery. Cartilage grafting should be considered for better flap support, to maintain nasal valve patency and to preserve nasal valve function. If greater than 50% of a nasal subunit has been excised, one should consider resecting the residual subunit for better aesthetic outcome. Good surgical planning and meticulous technique are imperative for optimal results.

Conflict of interest

The author declared no potential conflict of interest with respect to the research, authorship, and/or publication of this article.

References

1. Cerci FB, Nguyen TH. Paramedian forehead flap for complex nasal defects following Mohs micrographic surgery. *Surg Cosmet Dermatol* 2014; 6(1): 17–24.
2. Nguyen TH. Staged interpolation flaps. In: Roher TE, Cook JL, Nguyen TH, Mellele Jr, JR, (editors). *Flaps and grafts in dermatologic surgery*. New York: Elsevier; 2007. p. 91–105.
3. Jellinek NJ, Nguyen TH, Albertini JG. Paramedian forehead flap: Advances, procedural nuances, and variations in technique. *Dermatol Surg* 2014; 40 (Suppl 9): S30–S42. doi: 10.1097/DSS.000000000000112.
4. Burget GC, Menick FJ. The subunit principle in nasal reconstruction. *Plast Reconstr Surg* 1985; 76(2): 239–247. doi: 10.1097/00006534-198508000-00010.
5. Boyd CM, Baker SR, Fader DJ, Wang TS, Johnson TM. The forehead flap for nasal reconstruction. *Arch Dermatol* 2000; 136(11): 1365–1370. doi: 10.1001/archderm.136.11.1365.
6. Baker S. Internal lining. In: Baker S, Naficy S, (editors). *Principles of nasal reconstruction*. St. Louis: Mosby; 2002. p. 31–46.
7. Byrd DR, Otley CC, Nguyen TH. Alar batten cartilage grafting in nasal reconstruction: functional and cosmetic results. *J Am Acad Dermatol* 2000; 43(5 Pt 1): 833–836. doi: 10.1067/mjd.2000.107740.
8. Ratner D, Skouge JW. Surgical pearl: The use of free cartilage grafts in nasal alar reconstruction. *J Am Acad Dermatol* 1997; 36(4): 622–624. doi: 10.1016/S0190-9622(97)70253-6.
9. Cerci FB. Auricular cartilage graft for nasal reconstruction after Mohs micrographic surgery. *Surg Cosmet Dermatol* 2015; 7(2): 109–115. doi: 10.5935/scd1984-8773.201572649.
10. Newlove T, Cook J. Safety of staged interpolation flaps after Mohs micrographic surgery in an outpatient setting: a single-center experience. *Dermatol Surg* 2013; 39(11): 1671–1682. doi: 10.1111/dsu.12338.