



CASE REPORT

Granuloma due to sweet almond oil injection: Difficulties of diagnosis and treatment

Elisete Isabel Crocco^{1*}, Monique Dalapicola², Renata Diniz², Renata Alves¹, Rosana Lazzarini², Rute Lellis³

¹ Sector of Cosmetic Dermatology, Clinic of Dermatology, Santa Casa Medical Hospital and School of São Paulo, São Paulo-SP, Brazil

² Clinic of Dermatology, Santa Casa Medical Hospital and School of São Paulo, São Paulo-SP, Brazil

³ Pathology Department, Santa Casa Medical Hospital and School of São Paulo, São Paulo-SP, Brazil

Abstract: Foreign body granuloma reaction is a tissue response to some extraneous materials which incite a characteristic pattern of granulomatous reaction. Several cases of foreign body granulomas on the face have been reported, especially after the injection of dermal fillers. Oleoma or paraffinoma is defined as a foreign body granuloma resulting from the injection of oily substances into the skin or subcutaneous tissue. We report a case of an adult woman who had developed foreign body granulomas due to a self-injection of sweet almond oil into the glabella and periorbital area. The diagnosis was based on a thorough interrogation, clinical features and histopathological findings. Treatment of foreign body granuloma is challenging. At first, oral prednisone was initiated with the improvement of the inflammatory signs and reduction of the lesions' dimension, but recurrence of the lesions occurred when the dose was decreased. After research of literature, a low-dose minocycline regime was prescribed for its beneficial effects in granulomatous diseases, with encouraging results.

Keywords: silicone oils; foreign-body granuloma; minocycline; treatment; paraffinoma; granulomatous reaction

Citation: Crocco EI, Dalapicola M, Diniz R, Alves R, Lazzarini R, *et al.* Granuloma due to sweet almond oil injection: Difficulties of diagnosis and treatment. *J Surg Dermatol* 2020; 5(1): 110; <http://dx.doi/10.18282/jsd.v2.i3.110>.

*Correspondence to: Elisete Crocco, Av. Lavandisca, 777 – 10º andar. Moema, São Paulo, SP – Brazil, 04515-011; elisete@elisetecrocco.com.br.

Received: 8th October 2019; **Accepted:** 17th December 2019; **Published Online:** 18th January 2020

Introduction

Foreign body granuloma (FBG) reaction is a tissue response to some extraneous materials which incite a characteristic pattern of granulomatous reaction^[1]. Several cases of FBG on the face have been reported, especially after the injection of dermal fillers. However, we report a case of an adult woman who has developed FBG due to a self-injection of sweet almond oil into the glabella and periorbital area. The diagnosis was based on a thorough interrogation, clinical features and histopathological findings.

Treatment of FBG is difficult and various regimes have been used with a high rate of failure^[2]. Based on previous reports on FBG treated with minocycline for its beneficial effects in granulomatous diseases, we opted for its use as the main therapy in this case^[3,4].

Case report

A 51-year-old woman came to our department complaining of facial swelling, which was most pronounced around the left eye and the glabellar area. Erythematous, poorly circumscribed nodules were noted at those locations. They were not attached to the deeper tissues and presented an overlying erythema (**Figures 1A** and **1B**). According to the patient, the lesions appeared ten months prior as small, non-tender nodules that grew gradually over that period.

Sarcoidosis and cutaneous lymphoma were considered as possible diagnoses. The patient was submitted for skin biopsy, which showed granulomatous dermatitis with numerous histiocytes. The idea of infectious diseases as a cause was discarded after use of special stainings (Ziehl-Neelsen, PAS and Grocott).

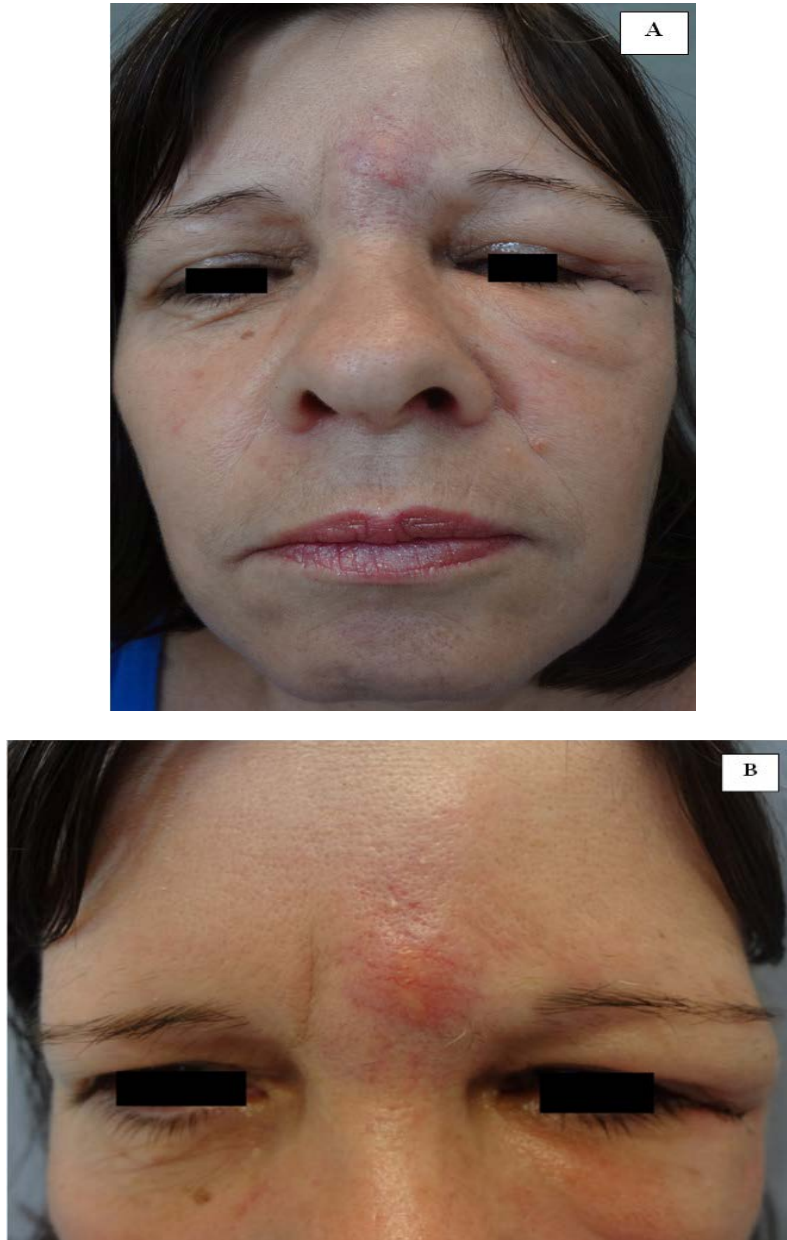

Figure 1. (A) and (B): Swelling and erythematous poorly circumscribed nodules around the left eye and the glabellar area

A new hypothesis of periorbital xanthogranuloma was suggested. However, immunohistochemistry did not confirm this diagnosis and excluded histiocytosis. The second biopsy revealed histiocytes multinucleate foreign body type whose cytoplasm displayed many vacuoles of sizes and different locations, without compromising perifollicular region (Figure 2).

After denying it many times, the patient finally admitted that she had self-injected sweet almond oil for aesthetic purposes. She claimed to have used her diabetic son's new syringe for the procedure.

A diagnosis of FBG was established and oral prednisone

(40 mg per day) was initiated and maintained for four weeks. Improvements of the inflammatory signs and reduction of the lesions' dimension were noted, but a recurrence occurred when the dose was decreased.

After literature research, a low-dose minocycline regime (100 mg once daily) was prescribed. Within four weeks of treatment, the swelling and erythema improved substantially. Minocycline was continued and 10 months after the initiation of the drug, the patient's condition was still improving, showing an excellent regression of induration and erythema (Figure 3). Side effects, such as pigmentation, did not occur.

Discussion

FBG reaction is a tissue response to some extraneous materials that incite a characteristic pattern of granulomatous reaction. There are several factors that may influence on clinical presentation regarding the injection of the material, such as mode of entry, tissue reaction to it and infection^[1,5].

Injection of oily materials can lead to the formation of FBG, also called as oleoma or paraffinoma. Several substances have been previously described as possible agents of oleoma: paraffin, petrolatum, vegetable oils, liquid petrolatum, hydrous wool fat (lanolin), sesame oil and beeswax^[6]. We describe a case of oleoma due to injection of sweet almond oil, a vegetable oil commercialized in regular pharmacies.

Histopathologically, FBGs may present as many different forms. Paraffinoma due to injection of oils results in a “Swiss cheese” appearance of holes containing lipids^[6]. There is variable fibrosis and granulomatous inflammation. Despite highly prevalent in granuloma, the presence of giant cells is not pathognomonic of the oleoma. Giant cells are the result of fusion of macrophages and can be found in others diseases^[5]. This can be similar to the reactions after the silicone implant, but can be differentiated based upon special fat staining, which is positive in paraffinoma.

Pathogenesis of FBG is still unknown. The injection of large volumes as a causative reason has been discussed but is still lacking statistical proof. FBG rate of almost all fillers decreased after products improvement over the years, showing the relationship between chemical and particulate impurities present in such products^[5].

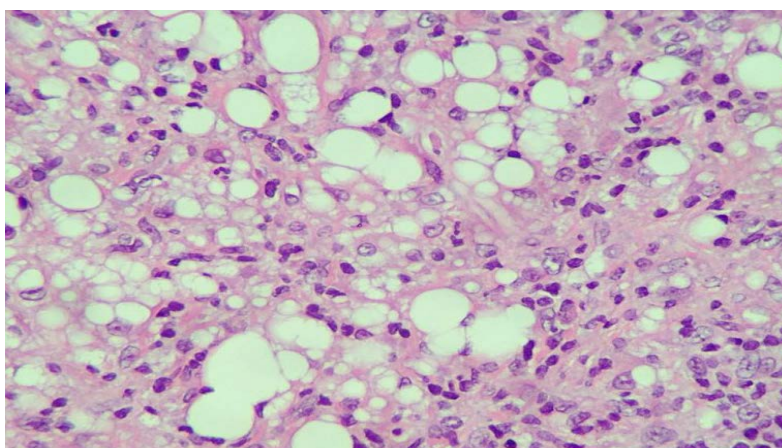


Figure 2. In histological section, there is histiocytic reaction with diffuse lymphocytic infiltrate. There are histiocytes multinucleate foreign body type whose cytoplasm displays many vacuoles of sizes and different locations.

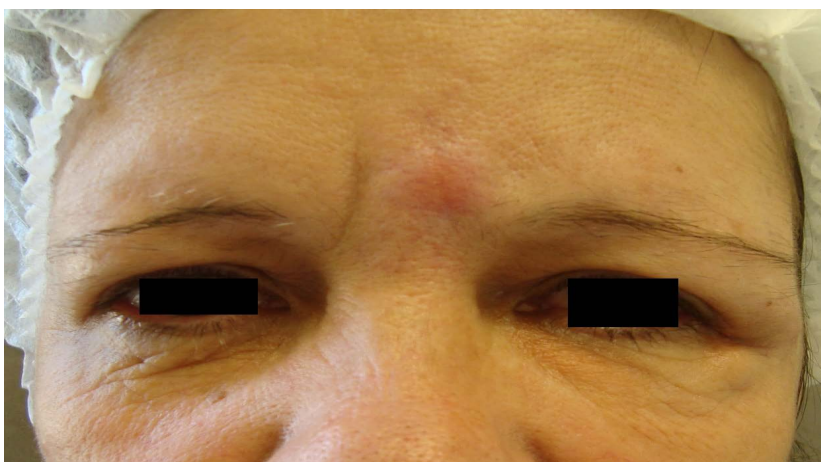


Figure 3. Improvement of the swelling and inflammatory characteristics of the nodules after the use of minocycline

Treatment of FBG is difficult and various regimes have been used. Surgical excision has been suggested; however, total removal may not be possible or may require extensive debridement^[2]. Injections of steroids or treatment with oral steroids have beneficial effects on the treatment of granulomatous diseases; however, a relapse is often seen when the dose is tapered^[3]. Retinoids, pentoxifylline and allopurinol have been used in some sporadic cases of FBGs, with variable results^[2].

In previous reports describing minocycline in the treatment of silicone granuloma, it was administered in a higher dose (100 mg twice daily) either as monotherapy or in combination with oral prednisone. The rationale for the administration of minocycline in granulomatous tissue reactions is its anti-inflammatory, immunomodulatory, and anti-granulomatous effect^[3,4]. Tetracycline, doxycycline and minocycline have anti-inflammatory properties secondary to their capacity in decrease production of neutrophil chemotactic cytokines. Minocyclines suppress T-cells, resulting in a dose-dependent inhibition of T-cell proliferation and a reduction in the production of IL-2, IFN- α and TNF- α . They suppress α -amylase and phospholipase A₂, which is important to activate inflammatory mediators as prostaglandins^[7].

Our data highlights the prolonged course of the disease, which sometimes necessitates treatment of long duration. This case supports a role for minocycline in the management of severe granulomas induced by foreign substance use, when surgical excision is not possible^[3]. In our opinion, minocycline monotherapy represents a useful treatment option for FBGs.

Conflict of interest

The authors declare no potential conflict of interest with

respect to the research, authorship, and/or publication of this article.

References

1. Bashir SJ, Chew SL. Mechanical injury to the skin. 9th ed. In: Griffiths CEM, Barker J, Bleiker T, Chalmers R, Creamer D (editors). *Rook's textbook of Dermatology*. Oxford: Wiley-Blackwell; 2016. p. 123.20.
2. Arin MJ, Bate J, Krieg T, Hunzelmann N. Silicone granuloma of the face treated with minocycline. *J Am Acad Dermatol* 2005; 52(2): S53-S56. doi: 10.1016/j.jaad.2004.07.014.
3. Senet P, Bachelez H, Ollivaud L, Vignon-Pennamen D, Dubertret L. Minocycline for the treatment of cutaneous silicone granulomas. *Br J Dermatol* 1999; 140(5): 985–987. doi: 10.1046/j.1365-2133.1999.02853.x.
4. Lemperle G, Gauthier-Hazan N. Foreign body granulomas after all injectable dermal fillers: Part 2. Treatment options. *Plast Reconstr Surg* 2009; 123(6): 1864–1873. doi: 10.1097/PRS.0b013e3181858f4f.
5. Lemperle G, Gauthier-Hazan N, Wolters M, Eisemann-Klein M, Zimmermann U, *et al.* Foreign body granulomas after all injectable dermal fillers: Part 1. Possible causes. *Plast Reconstr Surg* 2009; 123(6): 1842–1863. doi: 10.1097/PRS.0b013e31818236d7.
6. González-Sabín M, Almagro-Sánchez M, Iglesias-Conde R, Felgueiras-Magalhaes JL. Oleomas mimicking cutaneous xanthomas following breast augmentation by injection of liquid silicone. *J Dermatol Case Rep* 2014; 8(1): 13–15. doi: 10.3315/jdcr.2014.1163.
7. Perret LJ, Tait CP. Non-antibiotic properties of tetracyclines and their clinical application in dermatology. *Austral J Dermatol* 2014; 55(2): 111–118. doi: 10.1111/ajd.12075.