



ORIGINAL RESEARCH ARTICLE

Subungual glomus tumour excision: The nail plate flap technique

Sandeep Mehrotra¹, Vikas Singh^{1*}, Uday Singh Dadwal²

¹ Department of Plastic Surgery, Army Hospital (Research & Referral), New Delhi, India

² Specialist Surgery, Bahrain Specialist Hospital, Juffair, Manama, Bahrain

Abstract: Subungual glomus tumours, though rare, cause distressing symptoms and merit surgical treatment with minimal morbidity. Approaches to the nail bed over the years have varied from earlier nail excisions to trans/sub/periungual techniques. Nail plate preservation has beneficial effects on pain, and cosmesis and surgical modifications to ensure the same are desirable. We employed a simple nail preservation technique on six patients over the last seven years. After an accurate localization of the lesion based on pin test and Magnetic Resonance Imaging (MRI), a proximally-based nail plate flap was marked and elevated beyond the glomus. The tumour was removed through a linear nail-bed incision, following which the nail plate flap was repositioned without suturing. All cases had gratifying relief of symptoms. Within a few weeks of the excision, no nail distortion was noticeable. No recurrences were noted on follow-up for one year. The nail flap transungual approach relies on accurate preoperative tumour localization. It ensures a protective post-operative cover with reduced pain. A minimalistic approach with no skin incisions ensures less morbidity and improved cosmesis with no nail deformity. The nail plate flap technique can be employed in selected cases for improved outcomes.

Keywords: glomus tumour; subungual; nail plate; flap

Citation: Mehrotra S, Singh V, Dadwal US. Subungual glomus tumour excision: The nail plate flap technique. *J Surg Dermatol* 2021; 6(1): 136; <http://dx.doi.org/10.18282/jsd.v6.i1.136>.

*Correspondence to: Vikas Singh, Department of Plastic Surgery, Army Hospital (Research & Referral), New Delhi, India; vikastango21ster@gmail.com

Received: 3rd September 2020; **Accepted:** 4th December 2020; **Published Online:** 17th December 2020

Introduction

The glomus body is a physiological arteriovenous anastomosis which regulates blood flow and has a thermoregulatory function. Glomus tumours, which were described nearly two centuries ago, are small, commonly benign neoplasms frequently arising in the dermis or subcutaneous tissues of the extremities^[1]. Although not limited to the nail bed, 50%–75% occur subungually^[2]. The proliferation of this angiomatous tissue within the confined space of the nail bed results in exquisite pain. The classical triad of pain disproportionate to the lesion, severe tenderness and hypersensitivity to cold characterizes these lesions. Nail distortion, discolouration and bony changes are rarely prominent to be noted. The rarity of this tumour, coupled with low awareness and minimal objective findings, often leads to incorrect or delay in diagnosis. Literature attests that patients suffer for many years and are often subjected to irrational treatment prior to correct

management.

The excision of glomus tumour under the nail bed requires techniques for adequate exposure which necessitates dealing with the overlying nail. Approaches till recently relied on complete nail removal for ease of access and complete excision. This resulted in a tender, exposed fingertip and post-operative nail deformity. Alternate methods rely on trans/peri/subungual incisions with nail folding or resection for access. Resuturing of the removed nail is also resorted to for the protection of the raw area and to decrease pain. Variations of the transungual approach include subperiosteal excision and have been advocated for improved outcomes. Improved diagnostics and accurate localization permit precise surgery with pain-free and aesthetic outcomes. Recently, nail-preserving excisions have been described by flipping the proximal nail plate. We present a case series of six subungual glomus tumours managed over the last seven years by employing a simple proximally-based nail plate flap.

Materials and methods

All of the patients, referred over the last seven years with symptoms of subungual pain, tenderness or cold sensitivity suggestive of glomus tumour, were evaluated. Detailed histories of symptoms and treatments were taken and followed with clinical and radiological valuation. Magnetic Resonance Imaging (MRI) was done in all except one case. On confirmation of diagnosis, patients were advised surgery under wrist block. A finger tourniquet was employed by rolling down a cut loop of latex glove till the finger base. Magnification using a 4X loupe was employed on as-needed basis.

Surgical technique

Accurate pre-operative clinical mapping was done by employing Love's pin test. This is the test in which a pinhead was used to apply pressure to the lesion. The point at which intense pain was experienced would confirm the affected area containing the glomus tumour. This was

correlated with MRI findings, and the glomus site was hence marked precisely. A rectangular flap of nail plate was then marked over and beyond the glomus site. This was based proximally and elevated over the nail bed, leaving a rim of normal nail as a perimeter (**Figure 1A**). The underlying nail bed was incised in linear fashion at the flap bed and the glomus tumour was excised (**Figure 1B**). Following hemostasis and repair of the nail bed, the nail plate flap was replaced back and left unsutured (**Figures 1C and 1D**). This would allow any collection to leak out. A firm crepe dressing was placed over Vaseline gauze, and the patients were called for review on the next available slot in the Out-patient department (OPD). Oral analgesics were advised for three days and no antibiotics were administered. The dressing was changed at the first visit and patients were thereafter called for review after two weeks. Follow-up for nail growth and deformity was advised at three-month intervals for six months post-operatively. An OPD review or telephone follow-up was done after 12 months for symptoms or recurrence.

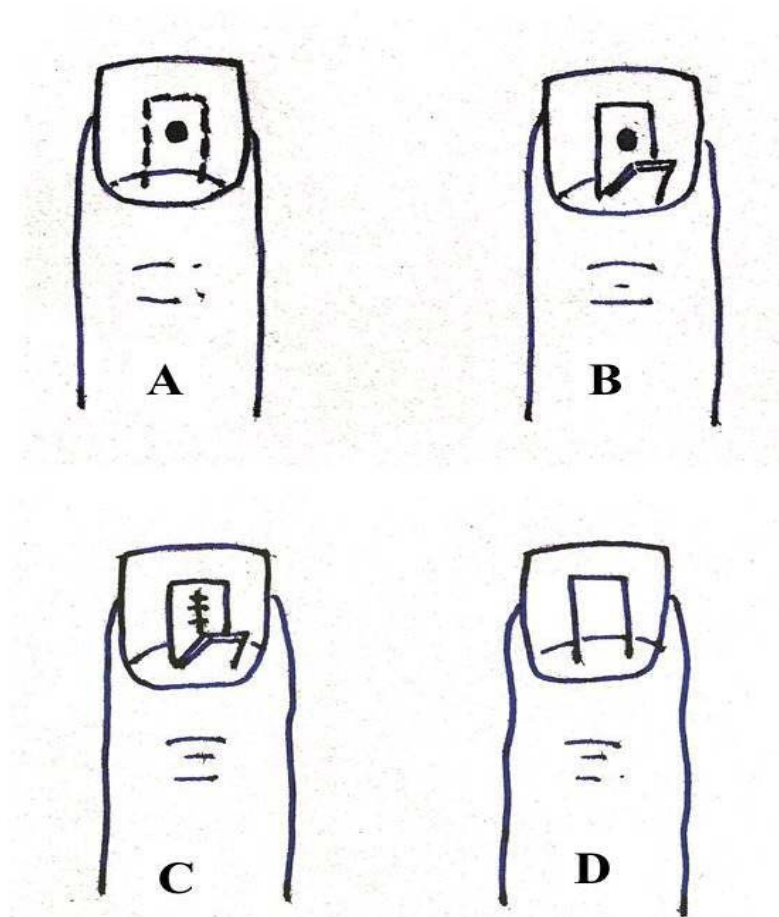


Figure 1. Clockwise from top left: (A) glomus and flap marking, (B) nail plate flap raised on proximal base to expose glomus, (C) tumour excision and nail bed repair, and (D) flap replacement on nail bed

Results

Our patients ranged from 16–54 (average: 32.7) years old and all were females. The right hand was involved in four patients. All patients presented with classic symptoms of exquisite pain and tenderness but only three cases had cold sensitivity. Symptoms' duration ranged from 1–6 years (average 2.8 years) and all patients had been to various practitioners for treatment. One young girl of 19 years old had been undergoing psychiatric consultation for a year prior to referral. X-rays were done in all cases and were reported as normal except in one case where terminal phalanx revealed erosion. All except one case underwent an MRI for confirmation and localization of lesion. The MRI showed a typical bright star enhancement in all scans.

Accurate MRI-based localization permits a nail-preserving proximal nail plate flap approach. This could be achieved in all six cases. The nail plate flap was raised beyond the lesion, leaving a perimeter of intact nail, and the glomus excised. The tumour was usually evident as a tense, well-limited, non-encapsulated pearly white swelling of 1–3

mm size (**Figures 2A** and **2B**). In all six cases, the planned flap encompassed the tumour and permitted complete excision. No nail plate flaps required alterations, additional nail incision or excision. All patients reported immediate relief of symptoms and appeared pleasantly surprised at the outcome. Two patients remained reluctant to touch the area out of fear till pain relief was demonstrated. Histopathological examination (HPE) confirmed glomus tumour in all six cases. Early follow-up revealed minimal discoloration at the flap bed, which resolved in 3–4 weeks (**Figure 2C**). No obvious nail deformity was evident after three months. Normal nail growth was observed in the operated digit, and was comparative to the normal remaining digits. This can be appreciated in the henna-coloured nails of one of our patients (**Figure 2D**).

Discussion

Glomus tumours are rare ectodermal tumours arising from the glomus body, which regulates blood flow and thermal regulation. Also called paragangliomas and by a

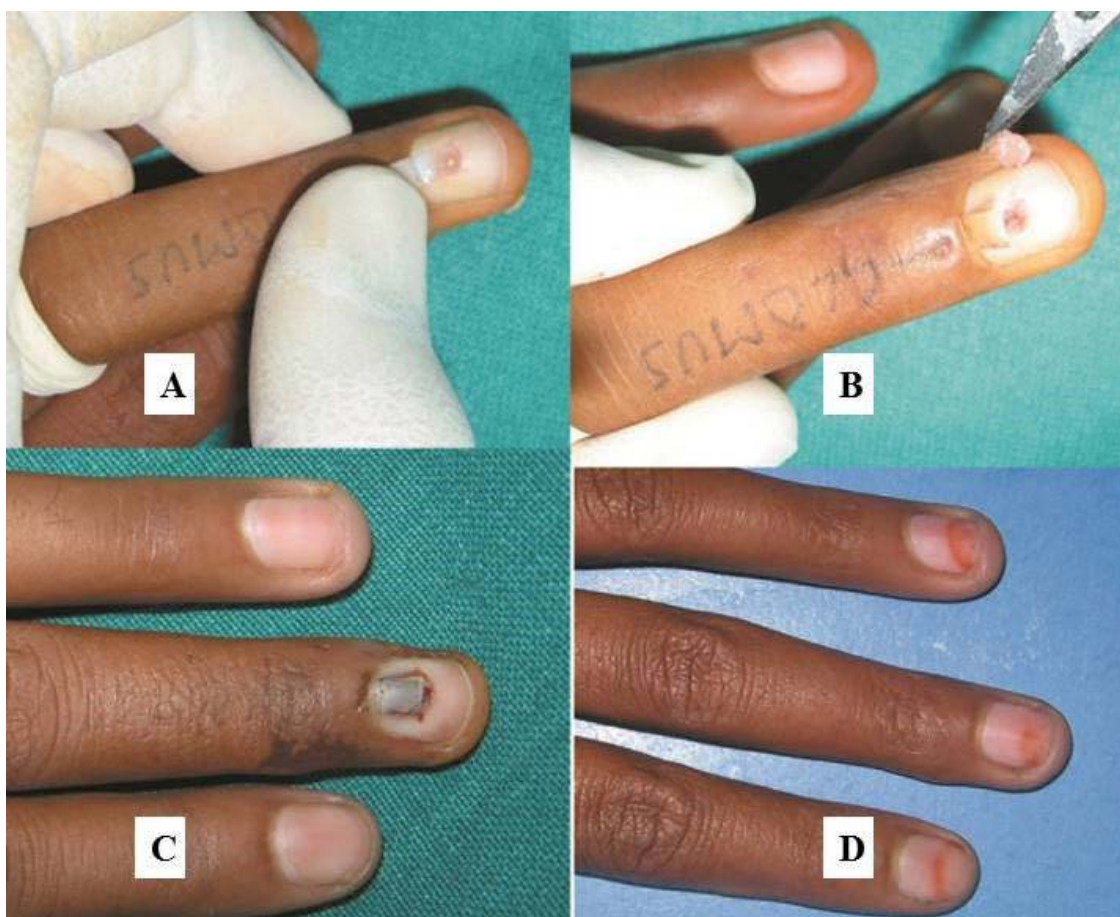


Figure 2. (A) A proximal-based rectangular nail plate flap was elevated and flipped back to expose the pearly white glomus. (B) Excision of the tumour; the raised flap was evident. (C) Two weeks post-operative, the unsutured repositioned flap was merging with the remaining nail plate. (D) Three months post-op; no obvious deformity was evident, with normal nail growth comparative to the other digits, as evident from the henna-stained nails.

variety of names such as chemodectomas, glomangioma or receptomas, they are notable by their rarity^[3]. Being of neural crest origins and part of the diffuse neuroendocrine system, the cells have similar functions and histological appearance. The glomus is a normal neuromyoarterial arteriovenous shunt with temperature regulation function^[4]. Sympathetic paragangliomas arise from the adrenal medulla and visceral autonomic ganglia whereas parasympathetic paragangliomas are found throughout the body.

The subungual location is classical, and it is rare to see a glomus tumour in soft tissues of other parts of the body. Very rarely, glomus tumours may display unusual features such as large size, deep location or infiltrative growth. Local invasion is exceptional, and malignancy and metastasis too are rarely reported^[5].

The surgical approach has undergone changes over the years, with greater concern for minimizing morbidity and improving cosmesis. A nail excision approach was employed till recently^[6]. Though ensuring wide exposure and complete excision, it left a tender and exposed nail bed, with chances of distorted nail if the matrix was injured. Resuturing of the excised nail was sometimes done to provide cover to the tender nail-exposed nail bed. This technique was gradually replaced by a subungual or periungual approach based on the tumour location^[7]. Nazerani *et al.* advised nail removal and replacement as a template following excision, while Tomak *et al.* advocated radial/ulnar incisions and folding of the nail^[8,9]. Nail ridging is a concern, and modifications using a subperiosteal approach have been advocated. Recently a nail-preserving approach has been described by Lee *et al.* The authors employed diagonal nail-fold incisions, with elevation and the flipping over of the proximal nail plate. After tumour removal, the nail plate was repositioned and folds resutured. The authors felt that a wide exposure permitted complete excision and decreased recurrences. They also recommended proximally-based nail flipping in cases of distal glomus tumours^[10].

We employed MRI for precise localization of the glomus. The characteristic image of glomus tumours on these scans is a high signal central dot surrounded by a zone of lower signal intensity^[11]. They show low signal intensity on T1-weighted images, high signal intensity on T2-weighted images, and enhancement on T1-weighted images after gadolinium injection. MRI is additionally useful as it delineates the size of the tumour and its precise location. Multiple lesions are also identified and this increases the chance of complete excision^[12]. The approach we have employed was simple and different compared to the nail-preserving surgery described by Lee *et al.* We raised a smaller flap from the insensate nail plate itself. We based this flap proximally over the pliable lunula and everted it for access to the nail bed and tumour. The flap was raised, ensuring that a perimeter cuff of healthy nail was retained all around (**Figure 1**). Following the nail bed incision, the tumour was delineated and excised. The nail bed was repaired and the nail plate flap repositioned over the same without suturing. On follow-up of our cases, there

was no evidence of nail deformity. The proximal-based nail plate flap technique appears to be a satisfactory option for subungual glomus, mainly the central lesions. There was no need to suture back the nail flap and we relied on a firm cohesive crepe bandage to ensure its repositioning. Though we did not have the occasion to do so, radial/ulnar- or distally-based nail plate flaps may be feasible in selected cases. The protective cover provided by the nail plate flap appears to have beneficial effects in pain relief and safety against trauma. As commonly agreed to, currently both pain relief and aesthesia are important considerations in managing subungual glomus tumours.

The nail flap technique requires precise pre-operative localization of the lesion. This can be achieved to within millimetric accuracy either clinically by a pin test or by MRI. Earlier operators did not have the luxury of pinpoint localization afforded by MRI, but the current easy availability of this technique and its typical findings ensure that nail plate flaps can be planned without risk of flap malpositioning, while also ensuring that multiple lesions, though rare, are not missed. This also prevents overly extensive excision that may induce further unnecessary trauma on the patient and lead to chances of post-operative nail deformity if the nail matrix is injured^[13]. We did not have the occasion to change our approach in any of the six cases including the one in which only clinical localization was done. No recurrences were observed on one-year follow-up.

Conclusion

It is felt that the nail plate flap approach may be a useful addition to the available surgical approaches in dealing with a subungual glomus, especially the central lesions. Though difficult to demonstrate the comparative efficacy of post-operative pain relief between the different approaches, it is reasonable to accept that at least an intact nail plate will be protective. The good cosmetic outcomes, which are apparent within weeks, are an added advantage of the minimalistic approach.

Conflict of interest

The author declares no potential conflict of interest with respect to the research, authorship, and/or publication of this article.

References

1. Bhaskaranand K, Navadgi BC. Glomus tumour of the hand. *J Hand Surg Eur Vol* 2002; 27(3): 229–233. doi: 10.1054/jhsb.2001.0746.
2. Rohrich RJ, Hochstein LM, Millwee RH. Subungual glomus tumours: An algorithmic approach. *Ann Plast Surg* 1994; 33(3): 300–304.
3. Million RR, Cassisi NJ, Mancuso AA. Chemodectomas (Glomus body tumours). In: Million RR, Cassisi NJ (editors). *Management of head and neck cancers: A multidisciplinary approach*. Philadelphia: JB Lippincott; 1984. p. 765.
4. Louis DN, Cavenee WK. Neoplasms of the central nervous system. 7th ed. In: DeVita VT, Hellman S, Rosenberg SA

-
- (editors). *Cancer: Principles and practice of oncology*. Philadelphia: Lippincott Williams & Wilkins; 2005. p. 1875–1876.
5. Folpe AL, Fanburg-Smith JC, Miettinen M, Weiss SW. Atypical and malignant glomus tumors: Analysis of 52 cases, with a proposal for the reclassification of glomus tumors. *Am J Surg Pathol* 2001; 25(1): 1–12. doi: 10.1097/00000478-200101000-00001.
 6. Moojen TM, Houpt P. Glomus tumours of the hand in the Netherlands: Analysis of 107 patients. *Eur J Plast Surg* 2000; 23(4): 224–226. doi: 10.1007/s002380050256.
 7. Takata H, Ikuta Y, Ishida O, Kimori K. Treatment of subungual glomus tumour. *Hand Surgery* 2001; 6(1): 25–27. doi: 10.1142/S0218810401000394.
 8. Nazerani S, Motamedi MHK, Keramati MR. Diagnosis and management of glomus tumours of the hand. *Techniques in Hand & Upper Extremity Surgery* 2010; 4(1): 8–13.
 9. Tomak Y, Akcay I, Dabak N, Eroglu L. Subungual glomus tumours of the hand: Diagnosis and treatment of 14 cases. *Scand J Plast Reconstr Surg Hand Surg* 2003; 37(2): 121–124. doi: 10.1080/02844310310005676.
 10. Lee HJ, Kim PT, Kyung HS, Kim HS, Jeon IH. Nail preserving excision for subungual glomus tumour of the hand. *J Plast Surg Hand Surg* 2014; 48(3): 201–204.
 11. Netscher DT, Aburto J, Koeplinger M. Subungual glomus tumor. *J Hand Surg Am* 2012; 37(4): 821–823. doi: 10.1016/j.jhssa.2011.10.026.
 12. Takemura N, Fujii N, Tanaka T. Subungual glomus tumor diagnosis based on imaging. *J Dermatol* 2006; 33(6): 389–393. doi: 10.1111/j.1346-8138.2006.00092.x.
 13. Tang CYK, Tipoe T, Fung B. Where is the lesion? Glomus tumours of the hand. *Arch Plast Surg* 2013; 40(5): 492–495. doi: 10.5999/aps.2013.40.5.492.