



ORIGINAL RESEARCH ARTICLE

## Floseal® use in dermatologic surgical management of vascular malformations: A novel haemostatic agent in Côte d'Ivoire

Komenan Kassi<sup>1,2</sup>, Vagamon Bamba<sup>3</sup>, Kouame Kanga<sup>1,2</sup>, Aang Allou<sup>2</sup>, Alexandre Kouassi<sup>1,2</sup>, Ildevert Patrice Gbery<sup>1,2</sup>, Sarah Kourouma<sup>1,2</sup>, Isidore Kouassi<sup>1,2</sup>, Elidje Joseph Ecra<sup>1,2</sup>, Mamadou Kaloga<sup>1,2</sup>, Abdoulaye Sangare<sup>1,2</sup>, Pauline Yoboue-Yao<sup>1,2</sup>, Jean-Marie Kanga<sup>1,2</sup>

<sup>1</sup> Department of Dermatology and Infectious Diseases, Training and Research unit of Medical Sciences, University of Felix Houphouet Boigny, Abidjan, République de Côte d'Ivoire

<sup>2</sup> Dermatology Department of Teaching Hospital of Treichville, Abidjan, République de Côte d'Ivoire

<sup>3</sup> Dermatology Department of Internal Medicine, University of Bouaké, République de Côte d'Ivoire

**Abstract:** A vascular malformation is a congenital growth of artery, venous, capillary or lymphatic vessels leading to functional and aesthetic problems. Although surgical maneuvers allow correction of abnormalities, it poses risk of intra and post-operative blood loss. Sealants have been used during surgical procedures to reduce blood loss. A descriptive study was conducted on a new generation Floseal® to demonstrate its effectiveness to reduce intra and post-operative bleeding during vascular malformation corrective surgery. A group of 19 patients presented with vascular malformations and underwent surgical correction associated with Floseal® use. The mean age of our patients' was 12.3 years (1 to 33 years). The majority of them (57.6%) were aged between 5 to 15 years. The most common vascular malformation treated was hemangioma (45.5%). Majority of these lesions were located on the head (72.7%). Blood transfusion was not accounted for in any of the cases as average blood loss was 18.18 mL (5 to 70 mL). The average length of hospital stay was 2.4 days. Ten patients (90.9%) were discharged in 2 days after drain was removed. Floseal®, a new generation local haemostatic, is easy to use and efficient to achieve haemostasis for treatment of vascular malformation. Haemostasis was achieved in a short time and blood loss was minimal. However, caution should be taken to reduce allergic reactions and potential viral transmissions, and further study should be done to recommend its use.

**Keywords:** vascular malformation; surgery treatment; Floseal® use

**Citation:** Kassi K, Bamba V, Kanga K, Allou A, Kouassi A, *et al.* Floseal® use in dermatologic surgical management of vascular malformations: A novel haemostatic agent in Côte d'Ivoire. *J Surg Dermatol* 2021; 6(2): 149; <http://dx.doi.org/10.18282/jsd.v6.i2.149>.

\*Correspondence to: Komenan Kassi, Department of Dermatology, Training and Research Unit of the University of Felix Houphouet Boigny of Abidjan, Cote d' Ivoire; [siskakomlo@yahoo.fr](mailto:siskakomlo@yahoo.fr), [komenan.kassi@univ-fhb.edu.ci](mailto:komenan.kassi@univ-fhb.edu.ci)

**Received:** 10<sup>th</sup> January 2021; **Accepted:** 30<sup>th</sup> March 2021; **Published Online:** 29<sup>th</sup> April 2021

### Introduction

A vascular malformation is a type of birthmark, or congenital vascular growth, made of arteries, venous, capillaries, or lymphatic vessels; that account for functional and aesthetical problems, because of its progressive nature<sup>[1]</sup>.

The treatment for vascular malformation depends upon the type of malformation. Laser therapy is effective for

capillary malformations, embolization is effective for artery malformations and sclerotherapy is effective for venous malformations. In all vascular malformations, surgery may be effective alone or in combination with non surgical methods, particularly at instances of incomplete removal. Previous studies state that preoperative embolization, sclerotherapy or laser therapy, can be performed prior to surgery and reconstruction<sup>[1,2]</sup>.

It may be noted that surgery leads frequently to intra or

post-operative bleeding that necessitates blood transfusion and prolonged hospital stay, which is also associated with high morbidity and mortality risk. To overcome these complications, some researchers recommend the use of local haemostatic agents composed of thrombin (bovine or human recombinant)<sup>[3,4]</sup>. In this frame, a new sealant was developed to control a pulsatile and other vascular bleedings. It is a fusion matrix haemostatic sealant that consists of a gelatin matrix mixed with thrombin. This sealant acts with a potential of swelling when in direct contact with blood. This adhesive contact leads to a compression at the bleeding site and achieves haemostasis within 10 min<sup>[5]</sup>. The aim of this study is to demonstrate the effectiveness and advantages of Floseal® (human recombinant thrombin) use in vascular malformation surgery to stop bleeding in intra and post-operative period during dermatologic surgery.

## Materials and methods

We conducted a descriptive study conducted over 6 months on patients diagnosed with vascular malformations in the Department of Dermatology, Teaching Hospital of Treichville.

All patients diagnosed with vascular malformations were enrolled after obtaining informed oral consent to undergo surgery. Prior to undergoing surgical correction, patients were evaluated with detailed clinical history, physical examination, standard blood testing, biological haemostatic analysis including D-dimer dosage, human genetic analysis for congenital abnormality, and radiologic examination such as: magnetic resonance imaging (MRI), positron emission tomography scan (PET-scan), Echodoppler and arteriography imaging.

Patients suspected with allergic reactions to any drugs (particularly bovine collagen component) in the past were excluded from the study.

All patients received pre-medication of heparin 3000 to 6000 international units as subcutaneous injection, to prevent coagulation disorders.

We used Floseal® which is a new generation local haemostatic<sup>[6]</sup>. This sealant contains:

- Human thrombin solution derived from pooled human plasma, with its biological activities of fibrinogen activation
- Gelatin based matrix from bovine collagen with micro granules. These micro granules represent the mechanical support for the product's capacity of self-expansion thereby leading to hemostasis.

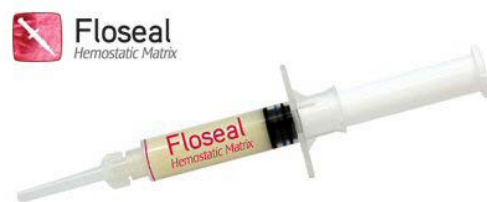Floseal® was used in intra operative setting and after excision. The first step was preparation of Floseal® by taking 5000 units of lyophilized human thrombin from a 5mL-syringe while using a 1-mL syringe with 0.8 mL of sterile saline solution. Then, the dispersion needle is assembled with the 1-mL syringe that contains gelatin matrix. Under steady movement (depression and pressure) of the plunger, the thrombin disperses into gelatin within 30 s. The mixture obtained (**Figure 1**) is used within 2 h.

Thereafter, Floseal® was put directly in contact with the bleeding surface through the syringe tip during the procedure. The surface was irrigated and the excess of Floseal® was removed. The reconstruction was conducted and surgical wound was dressed.

During follow-up, side effects were assessed and recorded (allergic reactions, viral or bacterial infections, etc.)

For data collection, the following parameters: demographic, clinical, intra and post-operative blood loss, complications, length of hospital stay, duration of drain removal, need for blood transfusion, and length of follow up was recorded.

The blood loss was estimated based on the blood loss from the operation site and the blood collected from the drain.



**Figure 1.** Floseal®, 5 mL of haemostatic matrix (Source: Baxter US)

## Ethics Statement

Oral consent was obtained from all patients to participate in the study. The local dermatological ethical committee has approved this study.

## Results

A group of 19 patients underwent (**Figures 2 and 3**) surgical correction for vascular malformations (coupled with Floseal®). Of these, one patient was noted for artery, lymphatic and venous malformation (ALVM) known as Klippel-Trenauney syndrome.

The average age of our patients was 12.3 years, ranging from 5 to 29 years old. There were more female patients (ten) than male patients (nine), with a sex ratio of 0.9, and majority of the vascular malformations was located on the head in 57.5% of cases (**Table 1**).

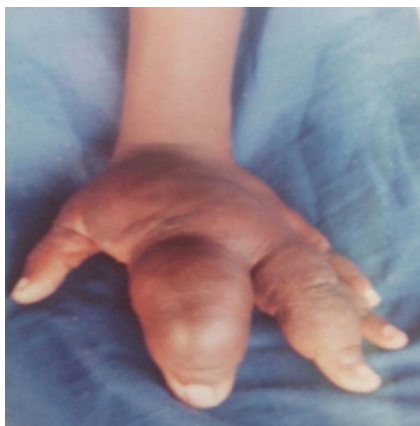We did not observe any allergic reaction or viral transmission, nor any necessity for blood transfusion in any of these cases. The overall intra and post-operative bleed ranged from 5 to 70 mL, with an average estimated to 18.18 mL.

The median length of the post-operative hospital stay was 2.4 days (1 to 7 days). Of all the patients, 18 patients (94.7%) were discharged and drains were removed in this time frame, while clinical state was good, and drains contained less than 20 mL of serum or blood discharge.

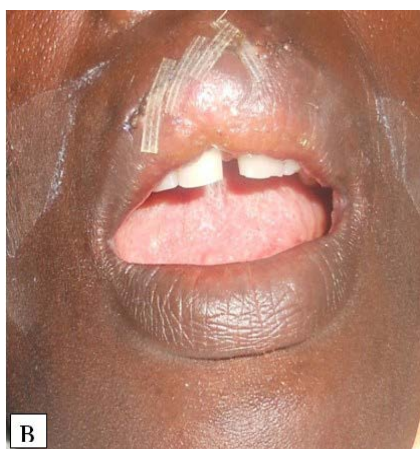
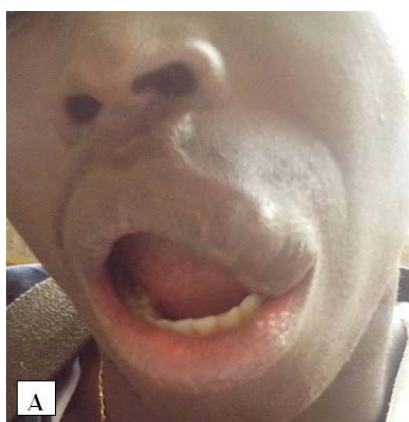
Only one patient (5.3%) was discharged with his drain because it contained about 90 mL of serum. It was removed

after one week of follow-up. The average duration of follow-up was 14 days (7 to 45 days). We did not find any side effects in pre and post-operative period.

We found only one post-operative complication as a pyoderma in a patient who presented an enormous lymphatic venous malformation in the arm (the Klippel-Trenauney syndrome) that was excised, drained. It healed within two weeks.



**Figure 2.** Vascular malformations: lymphatic and venous malformation of the hand



**Figure 3.** Venous malformation of the hyper lip: A (before) and B(after)

**Table 1.** Patient's baseline characteristics

Characteristics	Number (N=19)	Percentage (%)
<b>Sex</b>		
M	9	47.4
F	10	52.6
<b>Age (years)</b>		
[0–5]	4	21
[5–10]	7	36.8
[10–15]	2	10.5
[15–20]	3	15.8
[20–25]	1	5.3
[25–30]	1	5.3
[30–35]	1	5.3
<b>Type of vascular malformation</b>		
LM	2	10.5
LVM	3	15.8
VM	5	26.3
ALM	1	5.3
Hemangioma	8	42.1
<b>Location</b>		
Lower limb	3	15.8
Forearm	3	15.8
Arm	2	10.5
Head (forehead, cheek, nose, eyebrow)	11	57.9

**Abbreviations:** VM: venous malformation; LM: lymphatic malformation; LVM: lymphatic and venous malformation; ALVM: artery, lymphatic and venous malformation

## Discussion

Floseal<sup>®</sup> is a gelatin matrix combined with thrombin, it has the potential to swell (20% by volume), when in contact with blood. This mechanism allows the product to impart support, (by clot formation due to high concentration of thrombin) to keep the material in place and to provide compression to the bleeding tissue or surface thereby achieving haemostasis within approximately 10 min<sup>[5,6]</sup>. Floseal<sup>®</sup> was associated with a significantly higher rate of successful haemostasis and a shorter time to achieve haemostasis ( $p < 0.001$  for both) in comparison with the other alternatives when conventional methods failed in cardiovascular surgery<sup>[7,8]</sup>.

In our series, Floseal<sup>®</sup> use allowed us to achieve a good haemostasis in a short time. This observation could explain the early hospital discharge, i.e. within 2 days and no requirement for blood transfusion. Floseal<sup>®</sup> use is a simple and short procedure, as it is easily applicable onto the bleeding site or surface. Its use does not need specialized training. Some studies reported that Floseal<sup>®</sup> is useful in diverse specialties, including spinal, cardiac, renal, liver and spleen surgery, by controlling bleeding within 10min<sup>[9-12]</sup>

Moreover, Floseal<sup>®</sup> can be used in some inaccessible surgical sites, and in some critical patients with severe concomitant diseases or coagulation disorders, to provide

quick and effective haemostatic control.

In our series, we used the new component of Floseal® (human pooled plasma derived thrombin). This was advantageous in reducing the variety of complications related to bovine plasma derived use, ranging from laboratory abnormalities to potentially life threatening bleeding or thrombotic complications<sup>[13,14]</sup>. However it may be noted that Floseal® use could be limited by its cost. One box of Floseal® costs around 99 US dollars which is equal to more than 50,000 West African CFA franc, and proves to be expensive for poor patients without health insurance.

This was not an issue in our setting as all patients were covered by health insurance.

Although human pooled plasma-derived thrombin is less likely to cause allergic reactions when compared to bovine thrombin, it carries the risk of viral transmission like retrovirus, hepatitis viruses and parvovirus as well as prions during blood transfusion<sup>[13,15–16]</sup>.

These possible risks should be balanced against the benefit of Floseal® generation use, to achieve quick haemostasis in critical peripheral vascular bleeding conditions like artery or artery and venous or artery, venous and lymphatic malformations<sup>[17]</sup>. Therefore, Floseal® should be used as a local haemostatic agent in dermatologic surgery practice.

## Author contributions

All authors have contributed equally to the study's protocol design and writing the manuscript.

## Acknowledgments

We acknowledge all health care practitioners at the Dermatology Department of the Teaching Hospital of Trechville-Abidjan, République de Côte d'Ivoire, and all members of the Ivorian Society of Dermatology and Venereology

## Conflict of interest

The authors declare no potential conflict of interest with respect to the research, authorship, and/or publication of this article.

## References

1. Wassef M, Vanwijck R, Clapuyt P, Boon L, Magalon G. Tumeurs et malformations vasculaires, classification anatomopathologique et imagerie (French) [Vascular tumours and malformations, classification, pathology and imaging]. *Ann Chir Plast Esthet* 2006; 51(4–5): 263–281. doi: 10.1016/j.anplas.2006.07.017.
2. Boon LM, Vanwijck R. Traitement médical et chirurgical des malformations veineuses (French) [Medical and surgical treatment of venous malformations]. *Ann Chir Plast Esthet* 2006; 51(4–5):403–411. doi: 10.1016/j.anplas.2006.07.023.
3. Pace G, Sulduatto P, Vicentini C, Miano L. Haemostasis in surgery and our experience in enucleo resection of renal cell carcinoma. *World J Surg Oncol* 2010; 8: 37. doi: 10.1186/1477-7819-8-37.
4. Achneck HE, Sileshi B, Jamiolkowski RM, Aldala DM, Shapiro ML *et al.* A comprehensive review of topical haemostatic agents; efficacy and recommendations for use. *Ann Surg* 2010; 251(2): 217–228. doi: 10.1097/SLA.0b013e3181c3bcca.
5. Reuthebuch O, Lachat ML, Vogt P, Schurr U, Turina M. FloSeal®: Einneuartiges Hämostyptikum in der peripheren Gefäßchirurgie (German) [Floseal®: A new haemostyptic agent in peripheral vascular surgery]. *VASA* 2000; 29(3): 204–206. doi: 10.1024/0301-1526.29.3.204.
6. Spängler HP, Holle J, Braun F. Gewebeklebung mit Fibrin (German) [Tissue adhesion with fibrin. (An experimental study with rat skin grafts)] *Wien Klin Wochenschr* 1973; 85(50): 827–829.
7. Echave M, Oyagüez I, Casado MA. Use of Floseal®, a human gelatine-thrombin matrix sealant, in surgery: A systematic review. *BMC Surg* 2014; 14: 111. doi: 10.1186/1471-2482-14-111.
8. Yao HHI, Hong MKH, Drummond KJ. Haemostasis in neurosurgery: What is the evidence for gelatin-thrombin matrix sealant? *J Clin Neurosci* 2013; 20(3): 349–356. doi: 10.1016/j.jocn.2012.09.005.
9. Renkens KL, Payner TD, Leipzig TJ, Feuer H, Morone MA, *et al.* A multicenter, prospective, randomized trial evaluating a new haemostatic agent for spinal surgery. *Spine* 2001; 26(15): 1645–1650. doi: 10.1097/00007632-200108010-00002.
10. Nasso G, Piancone F, Bonifazi R, Romano V, Visicchio G, *et al.* Prospective, randomized clinical trial of the Floseal® matrix sealant in cardiac surgery. *Ann Thorac Surg* 2009; 88(5): 1520–1526. doi: 10.1016/j.athoracsur.2009.07.014.
11. Leixnering M, Reichetseder J, Schultz A, Figl M, Wassermann E, *et al.* Gelatin thrombin granules for haemostasis in severe traumatic liver and spleen rupture model in swine. *J Trauma* 2008; 64(2): 456–462. doi: 10.1097/TA.0b013e3180340de1.
12. Law LW, Chor CM, Leung TY. Use of haemostatic gel in postpartum hemorrhage due to placenta previa. *Obstet Gynecol* 2010; 116(2): 528–530. doi: 10.1097/AOG.0b013e3181e772cf.
13. Lawson JH. The clinical use and immunologic impact of thrombin in surgery. *Semin Thromb Hemost* 2006; 32(suppl): 98–110. doi: 10.1055/s-2006-939559.
14. The CoStasis Multi-center Collaborative Writing Committee. A novel collagen-base composite offers effective haemostasis for multiple surgical indications: Results of randomized controlled trials. *Surgery* 2001; 129(4): 445–450. doi: 10.1067/msy.2001.112365.
15. Burnouf T. Modern plasma fractionation. *Transfus Med Rev* 2007; 21(2): 101–117. doi: 10.1016/j.tmr.2006.11.001.
16. Eder G, Neuman M, Cerwenka R, Baumgarten K. Preliminary results of a randomized controlled study on the risk of hepatitis transmission of a two-component fibrin sealant (Tissucol/Tisseel). *Fibrin Sealant in Operative Med* 1986; 51–59.
17. Weaver FA, Lew W, Granke K, Yonehiro L, Delange B, *et al.* A comparison of recombinant thrombin to bovine as a haemostatic ancillary in patients undergoing peripheral arterial bypass and arteriovenous graft procedures. *J Vasc Surg* 2008; 47(6): 1266–1273. doi: 10.1016/j.jvs.2008.01.034.