

SHORT COMMUNICATION

IC plasty for reconstruction of axillary defect

Samir El Mazouz, Abdelmoughit Echchaoui*, Jaouad Hafidi, Nour-eddine Gharib, Abdellah Abbassi

Department of Plastic and Reconstructive Surgery, Mohammed V University, Ibn Sina University Hospital, Rabat, Morocco

Keywords: axillary hidradenitis suppurativa; axillary defect; IC plasty

Citation: El Mazouz S, Echchaoui A, Hafidi J, Gharib N, Abbassi A. IC plasty for reconstruction of axillary defect. J Surg Dermatol 2021; 6(1): 157; <http://dx.doi.org/10.18282/jsd.v6.i1.157>.

*Correspondence to: Abdelmoughit Echchaoui, Department of Plastic and Reconstructive Surgery, Ibn Sina University Hospital, Rabat 10000, Morocco; e.moughit@hotmail.fr

Received: 17th October 2020; Accepted: 27th November 2020; Published Online: 15th December 2020

Introduction

Reconstruction of axillary defects following surgery or trauma has always been a significant challenge for plastic surgeons. A variety of reconstruction options are available, including directed cicatrization, skin grafts and local flaps, but all of these procedures may allow skin contracture and leave unsightly scars^[1,2]. Free flap is a useful option but it requires an experienced surgical staff, expensive instruments and plenty of time.

IC plasty is a simple and reliable technique using the adjacent healthy skin for coverage of axillary defects. It was first described in 1960 by Colson *et al.*^[3], and then by Baux *et al.*^[4] in 1985 in the treatment of post-burn axillary contractures. This technique is a derivative of Z plasty, in which only one flap is transposed. The defect constitutes the I, while the C is drawn on intact skin (*e.g.* brachial or axillary region) after the determination of a neutral point not moving during the abduction of shoulder (point of rotation of the flap) (**Figure 1**). The C flap is elevated from the deep healthy skin, and transferred to the recipient site for covering axillary skin defect. The donor site is closed with a suction drain left in place^[5].

Case presentation

We report the case of a 17-year-old, right handed, without past medical history, presented with a severe, medically intractable, right axillary hidradenitis suppurativa for two years. Surgical removal of all the diseased skin left a large defect (**Figure 2**). Reconstruction was performed under general anesthesia with IC cutaneous brachial flap; post-operative courses were uneventful (**Figure 3**). The patient

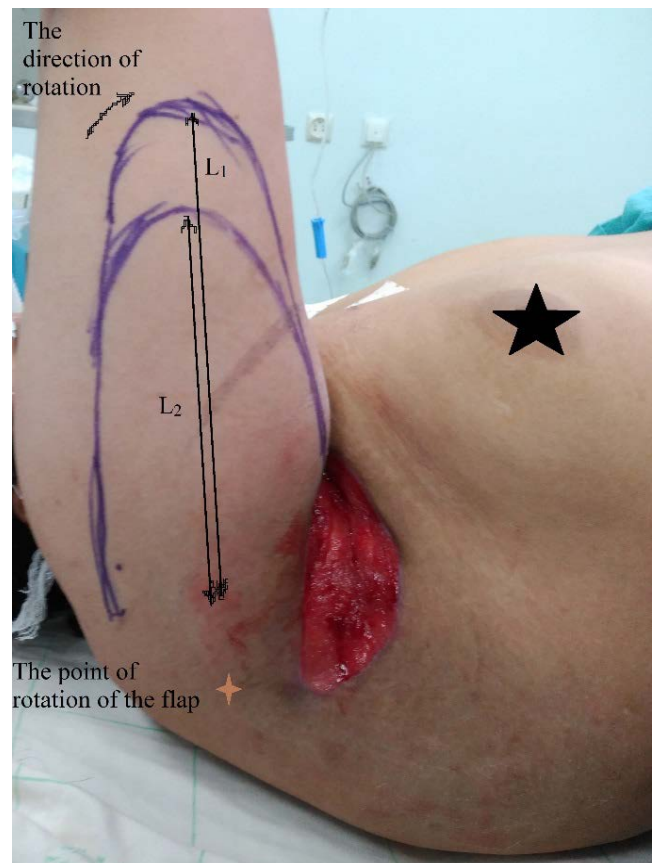


Figure 1. IC plasty design. L: The length of the flap depending on diameter of defect

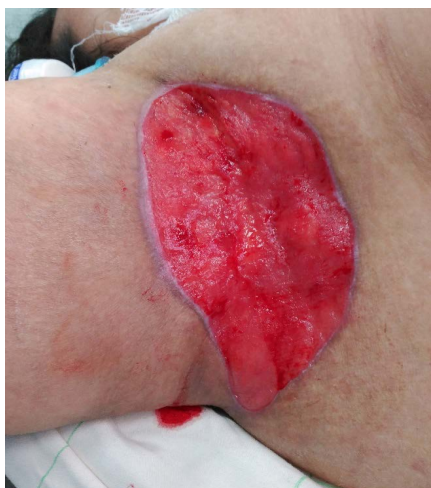

Figure 2. Right axillary defect following surgical excision of hidradenitis suppurativa

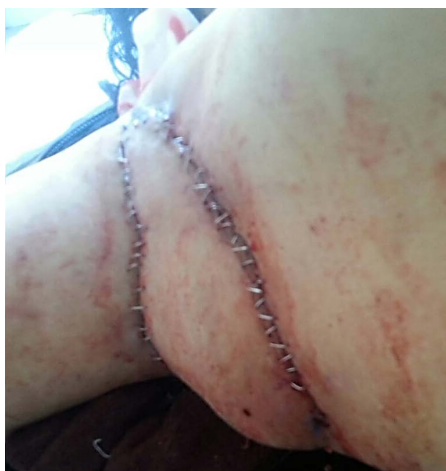

Figure 3. Immediate post-operative appearance

was followed-up clinically for three months; her shoulder mobility was perfectly preserved with a normal abduction.

IC plasty is a valuable and a versatile plasty, and its applicability can be extended to the other major joint defects (*e.g.* inguinal and popliteal fossae). It gives a successful functional outcome (a large range of joint mobility) if it is designed well and performed properly.

Conflict of interest

The authors declare no potential conflict of interest with respect to the research, authorship, and/or publication of this article.

References

1. Chuang CJ, Lee CH, Chen TM, Wang HJ, Chen SG. Use of a versatile transpositional flap in the surgical treatment of axillary hidradenitis suppurativa. *J Formos Med Assoc* 2004; 103(8): 644–647.
2. Geh JLC, Niranjana NS. Perforator-based fasciocutaneous island flaps for the reconstruction of axillary defects following excision of hidradenitis suppurativa. *Br J Plast Surg* 2002; 55(2): 124–128. doi: 10.1054/bjps.2001.3783.
3. Colson P, Gangolphe M, Hodut R, Leclercq P, Janvier H. (French) [Correction of retractions caused by burns of the axilla. Value of flap rotations in cases of average severity.] *Ann Chir Plast* 1960; 5: 1–8.
4. Baux S, Mimoun M, Kirsh JM, Zumer L, Auclair E. *Plastie en IC pour les rétractions axillaires après brûlures* (French) [IC plasty for axillary contractures following burns]. *Ann Chin Plast Esthet* 1988; 33(1): 86–90.
5. Joiucdar S, Kismoune H, Boudjemia F, Bacha D, Agrane A. *La plastie en ic dans les séquelles de brûlures des grosses articulations à propos de 150 cas* (French). *Ann Burns Fire Disasters* 2001; 14(1): 33–38.