



CASE REPORT

## Tuberculosis verrucosa cutis

Krishnabharath S

Department of General Surgery, Stanley Medical College & Hospital, Tamil Nadu, India

**Abstract:** We report a case of a 23-year-old male patient with tuberculosis verrucous cutis on the foot for a duration of six months without responding to routine treatment. Tuberculosis is a common disease worldwide. Tuberculosis verrucosa cutis is an exogenous infection occurring in a previously sensitized patient by direct inoculation of the organism. It occurs in sensitized patients with a moderate to high immune response. The diagnosis in our patient was confirmed by history, clinical examination, histopathological examination and the patient's response to anti-tuberculous therapy.

**Keywords:** tuberculosis verrucosa cutis; cutaneous tuberculosis; extrapulmonary tuberculosis; dermatologic manifestation

**Citation:** Krishnabharath S. Tuberculosis verrucosa cutis. J Surg Dermatol 2021; 6(1): 160; <http://dx.doi.org/10.18282/jsd.v6.i1.160>.

\*Correspondence to: Krishnabharath S, Department of General Surgery, Stanley Medical College & Hospital, Tamil Nadu, India; [drsaki85@gmail.com](mailto:drsaki85@gmail.com)

Received: 28<sup>th</sup> October 2020; Accepted: 9<sup>th</sup> January 2021; Published Online: 16<sup>th</sup> January 2021

### Introduction

Tuberculosis is a common disease worldwide. Extrapulmonary tuberculosis contributes to 10% of cases<sup>[1]</sup>. Cutaneous tuberculosis occupies a small spectrum of extrapulmonary tuberculosis. Tuberculosis verrucosa cutis is an exogenous infection occurring in a previously sensitized patient by direct inoculation of the organism. It occurs in sensitized patients with a moderate to high immune response<sup>[2]</sup>. We present a case of 23-year-old male patient with tuberculosis verrucous cutis on the foot.

### Case Report

A 23-year-old male presented with a plaque-like, verrucous hyperkeratotic skin lesion on the plantar aspect of the right foot for a duration of six months.

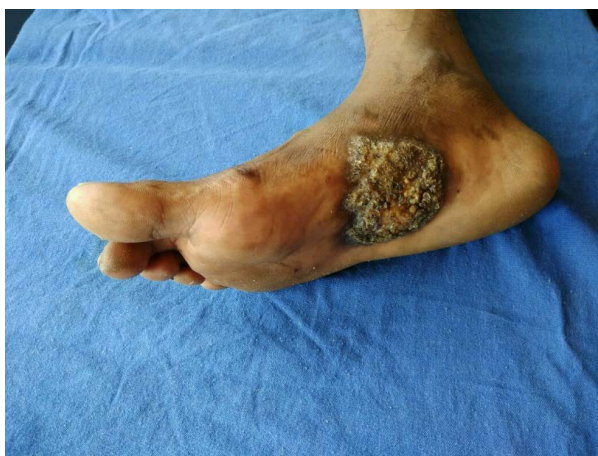The lesion initially appeared on the medial aspect of the right foot as a small plaque following a nail prick. After two months, the lesion started to progressively increase in size to become a verrucous lesion and he also noted a swelling in the groin region.

Local examination of the swelling revealed a well-defined, plaque-like, hyperkeratotic, verrucous lesion

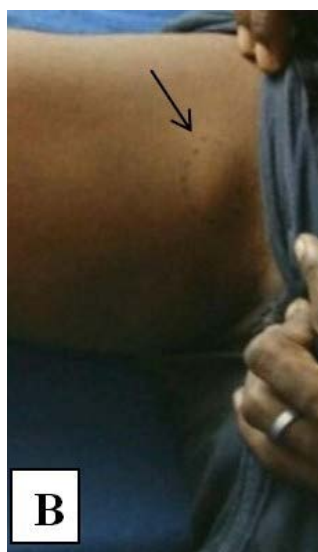
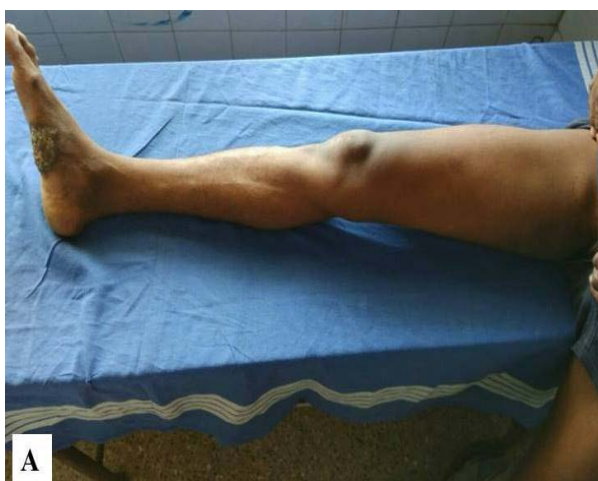with irregular surface of size 6 × 5.5 × 0.75 cm over the middle of the plantar aspect of the right foot (**Figure 1**). Examination of the right inguinal region revealed 3 × 3 × 1 cm firm swelling with smooth surface and well-defined margins (**Figure 2**).

Investigations revealed a normal hemogram and chest X-ray was normal; sputum examination was normal, Mantoux test was positive, the patient had BCG (Bacillus Calmette-Guérin) scar, and HIV (human immunodeficiency virus) and RPR (rapid plasma reagin) tests were negative. Fine-needle aspiration cytology of the right inguinal lymph node revealed small and large lymphocytes, abundant histiocytes and epithelioid granulomata in a haemorrhagic background, suggestive of granulomatous lymphadenitis. Biopsy of the specimen showed stratified squamous epithelium with strips of keratin and areas of haemorrhage.

The patient was diagnosed to have tuberculosis verrucosa cutis and started on WHO Category 1 anti-tuberculosis treatment (Isoniazid 600 mg, Rifampicin 450 mg, Pyrazinamide 1500 mg and ethambutol 800 mg thrice a week for two months followed by Isoniazid 600 mg and Rifampicin 450 mg twice a week for four months). The patient was discharged and advised to collect anti-tuberculosis treatment from nearby primary health centre.



**Figure 1.** The lesion on the right foot



**Figure 2.** (A and B) Right inguinal lymphadenopathy

The patient responded well, as the size of the lesion started to reduce with residual scarring.

## Discussion

Systemic tuberculosis has been known since ancient times. Its first description was given by Hippocrates (460–376 BC). Extrapulmonary tuberculosis contributes to 10% of the total tuberculous patients, out of whom cutaneous tuberculosis occupies a small spectrum, commonly affecting children and immune-compromised persons<sup>[3]</sup>. Cutaneous tuberculosis may be from:

1. Exogenous source
2. Endogenous source
3. Hematogenous spread
4. Tuberculids

Individuals vaccinated with BCG are at a higher risk of developing tuberculosis verrucosa cutis. In children, tuberculosis verrucosa cutis commonly occurs on knees, buttocks and thighs. It may also get inoculated in pathologists during an autopsy and hence called as “prosector’s wart”. The lesions of tuberculosis verrucosa cutis are usually asymptomatic and start as a small papule that slowly progress to verrucous or hyperkeratotic plaques over months. The histopathologic features of tuberculosis verrucosa cutis include pseudoepitheliomatous epidermal hyperplasia with hyperkeratosis and a dense infiltrate of neutrophils, lymphocytes and giant cells. The diagnosis of tuberculosis verrucosa cutis is difficult because of its paucibacillary nature. The response to anti-tuberculosis treatment may be taken as a diagnostic criterion. Adult men are more commonly involved because they are involved in manual work and are liable to injury<sup>[4]</sup>. Surgical intervention is not routinely advised<sup>[5]</sup>. In our case, the patient had a positive Mantoux test while chest X-ray and sputum examination were normal. The FNAC of inguinal lymph node showed granulomatous lymphadenitis and histopathological examination of lesion showed keratosis. The patient responded positively to the Category 1 anti-tuberculosis treatment, and the lesion showed a significant reduction in size.

## Conflict of interest

The author declares no potential conflict of interest with respect to the research, authorship and/or publication of this article.

## References

1. Bairagya TD, Das SK, Bhattacharaya S. Tuberculosis verrucosa cutis: A case report from a rural medical college of India. *Ann Trop Med Public Health* 2012; 5(4): 381–382. doi: 10.4103/1755-6783.102068.
2. Halim MS, Ahmed SQ, Junaid M, Bashir MR. Tuberculosis verrucosa cutis in a patient with keloid over ear lobule. *BMJ Case Rep* 2013; 2013: bcr2013010294. doi: 10.1136/bcr-2013-010294.

3. Barbagallo J, Tager P, Ingleton R, Hirsch RJ, Weinberg JM. Cutaneous tuberculosis. *Am J Clin Dermatol* 2002; 3(5): 319–328. doi: 10.2165/00128071-200203050-00004.
4. Vora RV, Diwan NG, Rathod KJ. Tuberculosis verrucosa cutis with multifocal involvement. *Indian Dermatol Online J* 2016; 7(1): 60–62. doi: 10.4103/2229-5178.174325.
5. Ghosh S, Aggarwal K, Jain VK, Chaudhuri S, Ghosh E, *et al.* Tuberculosis verrucosa cutis presenting as diffuse plantar keratoderma: An unusual sight. *Indian J Dermatol* 2014; 59(1): 80–81. doi: 10.4103/0019-5154.123511.