



ORIGINAL RESEARCH ARTICLE

Treatment of periorbital dark circles: Comparative study of chemical peeling with a combination of trichloroacetic acid and lactic acid versus carboxytherapy

Arwa Mohammad Hassan¹, Ghada Fawzy Rezk Hassan^{1*}, Hedaya Yousef Aldalies¹,
Gamal Mohammad El Maghraby²

¹Department of Dermatology and Venereology, Faculty of Medicine, Tanta University, Tanta, Egypt

²Department of Pharmaceutical Technology, Faculty of Pharmacy, Tanta University, Tanta, Egypt

Abstract: Periorbital dark circles (PODC) are a common worldwide cosmetic problem. It is difficult to treat due to complications in its pathogenesis and aetiology. Available lines of treatment for PODC include whitening creams, topical retinoid acid, chemical peeling, laser therapy, carboxytherapy, autologous fat transplantation, injectable fillers and surgery (blepharoplasty). The aim of this study is to evaluate and compare the efficacy of chemical peels using trichloroacetic acid (3.75%) and lactic acid (15%) in a gel formula with that of carboxytherapy, in the treatment of periorbital hyperpigmentation. Two groups of patients with PODC were included in the study, named Group A and B in which each group consisted of 15 patients. Group A was assigned for patients who received treatment with chemical peeling with a combination of trichloroacetic acid (3.75%) and lactic acid (15%) in a gel formula, once a week for four weeks. Group B was assigned for patients who received carboxytherapy that was performed by subcutaneous and intradermal injection of CO₂ once a week for four weeks. All patients were assessed by digital photographs, before and after treatment, by observing the improvement in the grade of PODC. Reports of patient satisfaction and global tolerance were evaluated by three medical observers. There was a significant improvement in the grade of PODC in both groups. The degree of improvement of PODC in group A was excellent, with good grade in 93.4% of the treated patients while fair grade in 6.6% of them. There was a statistically significant improvement in the pigmented type. The degree of improvement of PODC in group B was excellent, with good grade in 86.7% of the treated patients while fair grade in 13.3% of them. However, no statistically significant difference between the two groups was observed. Minimal and transient side effects were noticed; however, it did not require further treatment. In conclusion, the two methods of treatment were effective in the treatment of PODC, with the improvement of PODC observed from the first treatment session with both chemical peeling and carboxytherapy.

Keywords: Chemical peeling; carboxytherapy; periorbital dark circles

Citation: Hassan AM, Hassan GFR, Aldalies HY, El Maghraby GM. Treatment of periorbital dark circles: Comparative study of chemical peeling with a combination of trichloroacetic acid and lactic acid versus carboxytherapy. *J Surg Dermatol* 2016; 1(2): 108–115; <http://dx.doi.org/10.18282/jsd.v1.i2.29>.

*Correspondence to: Ghada Fawzy Rezk Hassan, Department of Dermatology and Venereology, Faculty of Medicine, Tanta University, 31111, Tanta, Egypt, ghadafawzy53@yahoo.com.

Received: 8th January 2016; **Accepted:** 28th February 2016; **Published Online:** 28th June 2016

Copyright © 2016 Hassan AM, *et al.* This is an Open Access article distributed under the terms of the Creative Commons Attribution-Non Commercial 4.0 International License (<http://creativecommons.org/licenses/by-nc/4.0/>), permitting all non-commercial use, distribution, and reproduction in any medium, provided the original work is properly cited.

Introduction

Periorbital dark circles (PODC) are known as bilateral homogeneous pigmentation on the periorbital areas. The condition is a common cosmetic problem affecting individuals of any age. Both sexes and any race can be affected. It becomes worse with the aging process and it can cause complaints of major annoyance, especially for female patients. PODC interferes with the appearance of the face, giving the patient a tired, sad look and an aging appearance^[1,2].

Hyperchromia of the periorbital area can be classified into primary (idiopathic) type and secondary type, which is associated with systemic or local diseases of known causes^[3]. Secondary PODC may be caused by multiple etiologic factors such as familial or ethnic tendency, periorbital edema and post-inflammatory hyperpigmentation, resulting from atopic or allergic contact dermatitis, medications and systemic diseases. Other causes that can be considered are fatigue, smoking, excessive sun exposure, superficial location of vasculature of the eye lids, tear trough depression and shadowing due to laxity of the skin^[1,2].

In fact, PODC can be a combination of the above - mentioned factors^[4]. On the other hand, it has been suggested that cutaneous hyperchromia of the orbital region is not associated with underlying diseases in many cases, as it can affect completely normal people^[5]. Available treatments for PODC include topical bleaching agents, chemical peeling, carboxytherapy, laser therapy, injectable fillers, autologous fat transplantation and surgery (blepharoplasty)^[6,7].

Chemical peeling is considered as a simple in-office technique. It is a medical procedure causing controlled damage to the skin, in which regeneration and rejuvenation of tissues occur after the healing process. It can be classified into three basic types according to the histologic depth of injury, i.e., superficial, medium and deep peeling. The first type affects only the epidermis down to the basal layer. The medium peel affects the papillary portion of the dermis, whereas the deep type can reach the reticular dermis. Chemical peels are widely used for depigmentation alone or in combination with other topical agents^[8].

Carboxytherapy is the administration of carbon dioxide (CO₂) gas for therapeutic purposes. It is used for the treatment of many cosmetic problems such as PODC, striae alba, improvement of cellulite, lipolysis, and rejuvenation of the face. It works by increasing blood flow to the injected region. Carboxytherapy also increases the deposition of collagen in the skin, giving the patient a young and healthy appearance^[9].

This study will evaluate the efficacy and safety of a novel superficial chemical peeling technique consisting

of a combination of trichloroacetic acid (TCA) 3.75% and lactic acid (LA) 15% in a gel formula (this combination increases the depth of penetration without using high concentration of the agents used, and has no adverse effects such as scarring and permanent depigmentation), and comparing it with carboxytherapy.

Methods

Upon approval from the research ethics committee of Faculty of Medicine of Tanta University (approval code 2655/08/14), this study was conducted on 30 patients with PODC, recruited from the Out-Patient Clinic of Dermatology and Venereology Department of Tanta University Hospital from August 2014 to March 2015. The patient inclusion criteria were namely patients with newly diagnosed cases who were otherwise clinically free, and patients not receiving any PODC treatment in the last six months. Patients with history of keloid scarring, bleeding tendency, and photosensitivity or hypersensitivity to the treatment components were excluded from this study. An informed consent was taken from every patient after full explanation of the procedure, risks and purpose of the study.

All patients were subjected to detailed history taking, thorough general and dermatological examination, evaluation of patient's skin type and evaluation before and after the treatment based on the type of PODC, i.e., whether it is pigmented (brown color), vascular (blue/pink/purple color) or mixed type. Assessment of the grade of PODC was conducted in comparison to the surrounding skin, which is as follows^[10]:

Grade 0: Skin color comparable to other facial skin areas.

Grade 1: Faint pigmentation of infraorbital fold (bilateral).

Grade 2: Pigmentation more pronounced.

Grade 3: Deep dark color, all 4 lids involved.

Grade 4: Grade 3 + pigmentation spreading beyond infraorbital fold.

The improvement was graded as 0% to 25% (poor), 26% to 50% (fair), 51% to 75% (good) and 76% to 100% (excellent), which was done by three medical observers. The patients were requested to estimate the clinical results and choose one out of the four categories: not satisfied, slightly satisfied, satisfied and very satisfied. Safety was assessed by evaluating global tolerance (poor, fair, good and excellent) and adverse effects. All patients were photographed before and after the treatment. The patients were divided into two groups named group A and B, with each group consisting of 15 patients.

Group A

A combination of peeling agents consisting of TCA in the concentration of 3.75% and LA of 15% was prepared in a gel formula^[11]. The patients were subjected to experience peeling every week for four weeks. Cleaning of the skin was carried out using a moistened wipe dampened with a combination of acidified hydroalcoholic solution with citric acid. For accurate application of the gel, a rigid device applicator covered with a thin spongy material was used. During every session, 4 layers of the peel were applied to periorbital area. The gel was applied for 1–2 min in the 1st, 2nd, and penultimate layer, and about 5 min in the last layer. The duration of each session was 8–11 min. Neutralization of the gel was done by a moistened wipe with 12% solution of arginine and the patients washed the treated area with pure water afterwards. All patients were advised to avoid rubbing the periorbital area, avoid sun exposure, use sunscreen and wear sunglasses.

Group B

Patients underwent a combination of intradermal and subcutaneous injections of CO₂ once a week for four weeks^[12]. The instrument used was carboxytherapy device (Concerto SN: CO 501-0600. Italy). The injections were performed bilaterally in the lateral upper and lower eyelid. A 32G needle was used to perform the injections. A total amount of gas was administered at 1–2 mL at each side, with flow rate of 1 cc/sec. The average time for each session was between 5–7 min. External compression was avoided, as it may lead to leakage of the gas through the skin. Routine follow-ups and evaluation of improvement for every patient were conducted every week throughout the treatment course for at least one month after finishing the treatment.

Statistical analysis

The collected data were organized, tabulated and statistically analyzed using Statistical Package for the Social Sciences (SPSS) software version 20. For qualitative data, comparison between two groups or more was done using Chi-square test (χ^2). For comparison between means of the two groups, parametric analysis (*t*-test) and non-parametric analysis (*Z* value of Mann-Whitney *U* test) were used. For comparison between means of the same group before and after treatment, parametric analysis (paired *t*-test) and non-parametric analysis (*Z* value of Wilcoxon Signed Ranks test) were used. A comparison

was done between two groups using the hypothesis test of proportions or *Z* test, by calculating the percentage of changes of pre- and post-treatment. Correlation between variables was evaluated using Pearson's correlation coefficient. The significance level was adopted at $p < 0.05$ for interpretation of the tested results^[13,14].

Results

30 female patients were included in the current study. They were divided into 15 patients in each group. Their age ranged from 18–50 years (median: 24). The duration of the disease was 3–10 years (median: 5) with no statistically significant difference found between the two studied groups.

Results of group A

The patients' skin types were presented as follows: 1 patient (6.7%) with skin type II, 10 patients (66.7%) with skin type III while 4 patients (26.6%) experienced skin type IV. The patients were categorized into several skin types, i.e., 8 patients (53.3%) with pigmented type of PODC whereas 7 patients (46.7%) with mixed type. Improvement in skin color was observed in most patients from the first session of peeling until further improvement thereafter. There was a statistically significant improvement in the grade of PODC ($p < 0.001$) as shown in **Table 1**.

All patients were satisfied with the treatment. None of the patients reported that PODC worsened after the treatment. The evaluation of every patient's degree of improvement by three medical observers revealed an excellent improvement in 46.7% of the patients (**Figure 1**), with good and fair results in 46.7% and 6.6% of them, respectively (**Figures 2 and 3**). Patient satisfaction result was as follows: very satisfied (33.3%), satisfied (53.3%) and slightly satisfied (13.3%). The procedure was tolerated with excellent global tolerance in 33.3% of the patients, whereas 46.6% and 20% of them showed good and poor tolerance, respectively, as shown in **Table 2**.

Some participants (40%) tolerated the chemical peeling treatment's minimal side effects known as tingling. On the other hand, 20% of patients experienced itching, 46.6% had mild burning sensation, while the other 33.3% and 20% of them had erythema, and exfoliation and dryness, respectively. The occurrence of exfoliation was most relevant at 24–48 h after the peeling treatment. However, all these symptoms existed for a short duration of time and did not require further treatment.

Table 1. Comparison between groups based on grade of PODC before and after treatment

	Chemical peeling (N = 15)		Carboxytherapy (N = 15)		Z	p	
	No.	%	No.	%			
Grade of PODC before treatment	0	0	0	0	Z = 0.726	0.468	
	1	2	13.3	2			13.3
	2	6	40.0	3			20.0
	3	5	33.3	8			53.3
	4	2	13.3	2			13.3
Grade of PODC after treatment	0	10	66.7	9	60.0	Z = 0.342	0.732
	1	4	26.7	5	33.3		
	2	1	6.7	1	6.7		
	3	0	0	0	0		
	4	0	0	0	0		
	Z	3.531*		3.482*			
p	< 0.001*		< 0.001*				

Z: Z value for Mann Whitney test

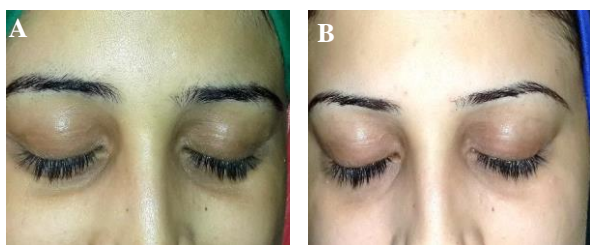


Figure 1. Patient with PODC as seen before (A), and after (B), chemical peeling treatment, who was diagnosed as pigmented type grade 3 PODC and showed excellent improvement

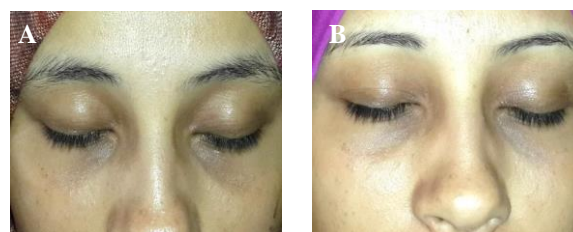

Figure 3. Patient with PODC as seen before (A), and after (B), chemical peeling treatment, who was diagnosed as pigmented type grade 3 PODC and showed fair improvement

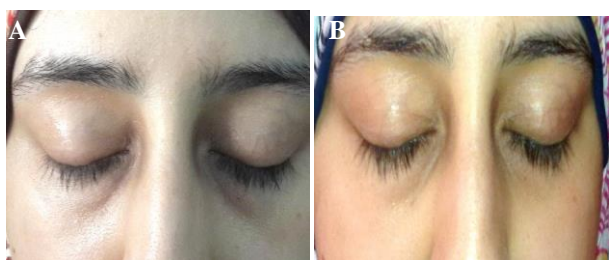

Figure 2. Patient with PODC as seen before (A), and after (B), chemical peeling treatment, who was diagnosed as pigmented type grade 3 PODC and showed good improvement

The relationship between type of PODC and its degree of improvement showed significant improvement in pigmented type of PODC ($p = 0.005$) as shown in **Table 3**.

Results of group B

The patients' skin types were presented as follows: 5 patients (33.3%) with skin type II, 7 patients (46.7%) with skin type III and 3 patients (20%) with skin type IV. The patients were divided into several skin types, i.e., 7

patients (46.7%) with pigmented type of PODC, 6 patients (40%) with mixed type, and 2 patients (13.3%) with vascular type. The patients reported improvement in both PODC and wrinkles. There was a statistically significant improvement in the grade of PODC ($p < 0.001$) as shown in **Table 1**.

The evaluation of every patient's degree of improvement by three medical observers reported an excellent result in 46.7% of the patients (**Figure 4**), with good and fair results in 40% and 13.3% of them, respectively (**Figures 5 and 6**). The patient satisfaction result was as follows: very satisfied (40%), satisfied (53.3%) and slightly satisfied (6.7%). The procedure was tolerated with excellent global tolerance in 33.3% of the patients, whereas 53.3% and 13.3% of them showed good and poor tolerance, respectively, as shown in **Table 2**.

Most participants (33.3%) tolerated carboxytherapy treatment with minimal side effects of minor pain at site of injection; however, the pain was temporary and limited to the site of injection. Edema was found in 26.6% of the patients (which totally disappeared 10 min after the

session; however, it continued for 24 h in a few patients), 20% experienced burning sensation, whereas 6.6% reported mild ecchymosis. All of these side effects were only temporary and most of the patients tolerated it very well.

The relationship between type and degree of improvement of PODC was presented in Table 3 and shows no significant difference in the improvement of different type of PODC.

Table 2. Comparison between groups according to degree of improvement, patient satisfaction and global tolerance

	Chemical peeling (N = 15)		Carboxytherapy (N = 15)		χ^2	MC <i>p</i>
	No.	%	No.	%		
Degree of improvement						
Poor response (0%–25%)	0	0.0	0	0.0	0.540	1.000
Fair response (26%–50%)	1	6.6	2	13.3		
Good response (51%–75%)	7	46.7	6	40.0		
Excellent response ($\geq 76\%$)	7	46.7	7	46.7		
Patient satisfaction						
Not satisfied	0	0.0	0	0.0	0.555	1.000
Slightly satisfied	2	13.3	1	6.7		
Satisfied	8	53.3	8	53.3		
Very satisfied	5	33.3	6	40.0		
Global tolerance						
Poor	0	0.0	0	0.0	0.394	1.000
Fair	3	20.0	2	13.3		
Good	7	46.6	8	53.3		
Excellent	5	33.3	5	33.3		

χ^2 : value for Chi square; MC: Monte Carlo test

Table 3. Relationship between degrees of improvement and type of PODC

Type of PODC	Degree of improvement						χ^2	<i>p</i>	
	Fair		Good		Excellent				
	No.	%	No.	%	No.	%			
Group A	Mixed	1	100.0	6	85.7	0	0.0	10.500*	0.005*
	Pigmented	0	0.0	1	14.3	7	100.0		
	Vascular	0	0.0	0	0.0	0	0.0		
Group B	Mixed	1	50.0	2	33.3	3	42.9	3.296	0.742
	Pigmented	1	50.0	4	66.7	2	28.6		
	Vascular	0	0.0	0	0.0	2	28.6		

χ^2 : Chi square test; FE: Fisher Exact test; *Statistically significant at $p \leq 0.05$

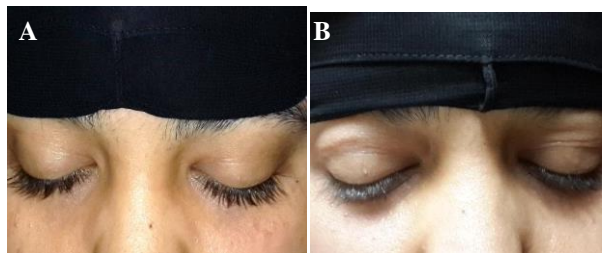


Figure 4. Patient with PODC as seen before (A), and after (B), the treatment of carboxytherapy, who was diagnosed as pigmented type grade 2 PODC and showed excellent improvement

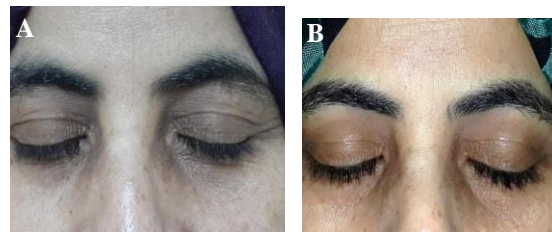

Figure 5. Patient with PODC as seen before (A), and after (B), the treatment of carboxytherapy, who was diagnosed as pigmented type grade 3 PODC and showed good improvement overall especially in the periorbital wrinkles area

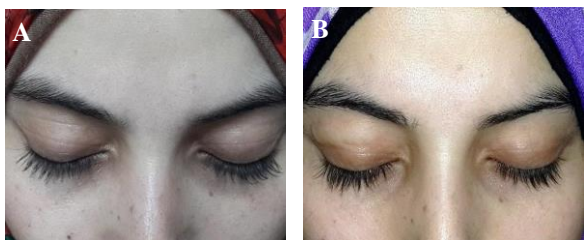

Figure 6. Patient with PODC as seen before (A), and after (B), the treatment of carboxytherapy, who was diagnosed as pigmented type grade 2 PODC and showed fair improvement

Comparison between group A and B

There was no statistically significant difference in the improvement of the PODC grade between the groups, as shown in [Table 1](#). The degree of improvement of PODC, patient satisfaction and global tolerance also showed no statistically significant difference between the two studied groups ([Table 2](#)). In addition, there was no significant correlation between either age or duration of the PODC and degree of improvement in both groups.

Discussion

The etiology of PODC may be multifactorial with none of the etiologic agent predominating. That is why there is no treatment of choice for PODC; in truth, published research are still deficient with regard to this problem^[15,16].

Chemical peeling is a simple in-office procedure that has evolved over the years. It is based on causing chemical injury to the skin that leads to the regeneration of new healthy layers. It is a simple and cheap technique which needs fewer instruments to rejuvenate the skin^[17].

Although carboxytherapy is widely used in many fields, only a few researches concerning its application in aesthetic medicine were published. It was discovered that it improves skin elasticity, circulation, aids collagen repair and destroys localized fatty deposits^[18].

In the current study, the degree of improvement of PODC treated with chemical peeling in group A was found to be excellent in 46.7% of the patients, while showing good and fair result in 46.7% and 6.6% of them, respectively. None of the patients' skin became worse or did not respond to the treatment. Statistically significant improvement in the grade of PODC was reported ($p < 0.001$). This result was even better than the results of a previous study by Vavouli *et al.* who performed chemical peeling with the same chemical combination for infraorbital dark circles. They reported an excellent response in 16.6% of the patients, while 40.0%, 36.7%

and 6.6% of them showing good, fair and poor result, respectively^[11].

In the present study, 33.3% of the studied patients were very satisfied with the results, 53.3% were satisfied and 13.3% were slightly satisfied. This was in agreement with the study by Vavouli *et al.*, in which they reported that the patient satisfaction result was 63.3% responded to be very satisfied, with slightly satisfied in 23.3% of them, while the other 13.3% were dissatisfied^[11].

In this study, the patient global tolerance was found to be 33.3% excellent, 46.6% good and 20% fair in the patients, respectively. This finding was in accordance with Vavouli *et al.*, who reported 46.7% excellent tolerance in the patients, while 30.0% and 23.3% of them showed good and fair tolerance, respectively^[11].

The side effects were minimal and listed as transient in the patients. 46.6% of patients experienced burning sensation, 40% had tingling, 33.3% presented with erythema, 20% manifested itching and the other 20% had skin dryness. At the same time, Vavouli *et al.* discovered the same side effects which were not considered as restrictive factor to the patients^[11]. This was the first study to find out that this combination of chemical peeling was significantly much more effective for PODC of pigmented type as compared to other types.

This could be explained by the fact that TCA application on the skin produces injury to the epidermis and upper dermis, as well as coagulation of skin proteins and melanin dispersion. This is followed by regeneration of new cells with increased collagen formation, which leads to the increase in the volume of epidermis and dermis. Many factors affect the depth of skin necrosis such as the increase in the concentration of TCA, application of TCA on a more permeable skin, increase in the number of skin layers used in the same treatment session, prolongation of contact time with the skin, the number of previously performed sessions, the duration between sessions, and the patient's skin type^[19].

Lactic acid is an alpha hydroxy acid (AHA) which facilitates desquamation of epidermal cells, melanin dispersion, and induces collagen and glycosaminoglycan deposition. Moreover, it has been reported to inhibit tyrosinase enzyme; therefore it was used in the treatment of melasma^[20]. It induces the skin-lightening effect through three mechanisms, namely the induction of keratinocytes desquamation and the removal of melanosomes; the inhibition of tyrosinase; and the thickening of the epidermis and the dermis, so that the vasculatures become less visible^[21,22].

There are several advantages of the combination of chemical peels: for instance, increasing the depth of skin penetration without increasing the concentration of chemical peels; lowering the treatment's adverse effects

such as scarring and permanent depigmentation by using low concentration of the peeling agents; enhancing tissue regeneration; and reducing subsequent recovery time^[11].

Additionally, this chemical peel is reliable and an effective method of treatment for PODC, especially the pigmented type. It is cheaper when compared to other methods. It has the advantage of well-homogenizing effect. It is also effective, safe, and well tolerated, which is satisfying for both patients and physicians^[11]. However, the only limitation for this kind of treatment is that the patients should avoid sun exposure.

The degree of improvement of PODC for group B treated by carboxytherapy was excellent in 46.7% of the patients, while showing good and fair results in 40% and 13.3% of them, respectively. None of the patients' skin was worsening or not responding to the treatment. A statistically significant improvement in the PODC grade was reported ($p < 0.001$). The patient satisfaction result was as follows: 53.3% satisfied, 40% very satisfied and 6.7% slightly satisfied. On the other hand, the patient global tolerance was as follows: 33.3% excellent, 53.3% good and 13.3% fair. The side effects were minimal and listed as transient, with 33.3% of the patients having pain at the site of injection, 26.6% having edema, 20% experiencing burning sensation and 6.6% manifesting ecchymosis, while two patients did not report any complaints.

This was in accordance with the results of a previous study by Paolo *et al.* who performed carboxytherapy for PODC^[12]. The compliance of the patients was good and they tolerate the procedure well. They reported a progressive improvement of periorbital wrinkles as well as periorbital pigmentation from the first treatment session with continuous improvement after that. In the present study, we found that the patients' wrinkles also improved and their skin textures became better. We also reported an excellent improvement in the vascular type of PODC, which occurred in two cases only.

Carboxytherapy is a new technique that consists of the subcutaneous and intradermal injection of CO₂. The injected CO₂ creates a relative state of hypercapnia which is compensated by vasodilatation and increment in the capillary blood flow to the injected area, reduces cutaneous oxygen consumption, as well as stimulates growth factors secretion such as vascular endothelial growth factor (VEGF), leading to new blood vessels formation. The state of hypercapnia is not harmful to the body because it can be simply eliminated via lungs^[23].

Carboxytherapy is very beneficial in restoring the physiology of the lymphatic system in patients complaining of having lymphatic stasis as its vasodilation effect enhances tissue perfusion and improves local parameters of circulation resulting in the reduction of

lymphedema^[24,25]. It also increases collagen turnover as reported by Paolo *et al.*, as their patients showed reduction in periorbital wrinkles and facial lines with improvement in skin texture as well^[12].

This was the first study to compare between chemical peeling and carboxytherapy in the treatment of PODC. There was no significant difference between the groups regarding the grade of PODC before and after the treatment. The degrees of improvement of PODC showed no statistically significant difference between the two studied groups. There was no significant difference between the studied groups and both the patient satisfaction and global tolerance results.

Conclusion

We concluded that the two methods of treatment were equally effective in the treatment of PODC, with the improvement of PODC observed from the first treatment session for both chemical peeling and carboxytherapy. Chemical peeling was much better in the treatment of pigmented type of PODC, with minimal tolerated side effects. It is cheap and is considered as a simple in-office technique. On the other hand, carboxytherapy is an effective and novel method for the treatment of PODC especially in the cases of patients with periorbital wrinkles. Nevertheless, expensive treatment sessions may be a limiting factor for such method. Additional studies are recommended on a larger number of patients with PODC to get better evaluations.

Author contributions

The idea of the study was that of Hassan AM. The design of the study, collection of patients, the sessions that were done for the patients were performed by Hassan AM, Hassan GFR, Aldalies HY, The preparation of the gel used for peeling was done by El Maghraby GM. Also, the analysis and interpretation of data; drafting the article and revising it critically for important intellectual content; and final approval of the version to be published were done by all authors.

Conflict of interest

The authors declared no potential conflict of interest with respect to the research, authorship, and/or publication of this article.

References

- Freitag FM, Cestari TF. What causes dark circles under the eyes? *J Cosmet Dermatol* 2007; 6(3): 211–215. doi: 10.1111/j.1473-2165.2007.00324.x.
- Roh MR, Chung KY. Infraorbital dark circles: Definition, causes, and treatment options. *Dermatol Surg* 2009; 35(8): 1163–1171. doi: 10.1111/j.1524-4725.2009.01213.x.
- Cymbalista NC, de Oliveira ZNP. Treatment of idiopathic cutaneous hyperchromia of orbital region (ICHOR) with intense pulsed light. *Dermatol Surg* 2006; 32(6): 773–784. doi:10.1111/j.1524-4725.2006.32160.x.
- Roh MR, Kim TK, Chung KY. Treatment of infraorbital dark circles by autologous fat transplantation: A pilot study. *Br J Dermatol* 2009; 160(5): 1022–1025. doi: 10.1111/j.1365-2133.2009.09066.x.
- Yeh CC, Williams III EF. Midface restoration in the management of the lower eyelid. *Facial Plast Surg Clin North Am* 2010; 18(3): 365–374. doi: 10.1016/j.fsc.2010.04.001.
- Momosawa A, Kurita M, Ozaki M, Miyamoto S, Kobayashi Y, *et al.* Combined therapy using Q-switched ruby laser and bleaching treatment with tretinoin and hydroquinone for periorbital skin hyperpigmentation in Asians. *Plast Reconstr Surg* 2008; 121(1): 282–288. doi: 10.1097/01.prs.0000293869.00522.ec.
- Rigopoulos D, Gregoriou S, Katsambas A. Hyperpigmentation and melasma. *J Cosmet Dermatol* 2007; 6(3): 195–202. doi:10.1111/j.1473-2165.2007.00321.x.
- Khunger N. Standard guidelines of care for chemical peels. *Indian J Dermatol Venereol Leprol* 2008; 74(7): 5–12.
- Brandi C, D’Aniello C, Grimaldi L, Caiazzo E, Stanghellini E. Carbon dioxide therapy: Effects on skin irregularity and its use as a complement to liposuction. *Aesthet Plast Surg* 2004; 28(4): 222–225. doi: 10.1007/s00266-004-2068-z.
- Sheth PB, Shah HA, Dave JN. Periorbital hyperpigmentation: A study of its prevalence, common causative factors and its association with personal habits and other disorders. *Indian J Dermatol* 2014; 59(2): 151–157. doi: 10.4103/0019-5154.127675.
- Vavouli C, Katsambas A, Gregoriou S, Teodor A, Salavastru C, *et al.* Chemical peeling with trichloroacetic acid and lactic acid for infraorbital dark circles. *J Cosmet Dermatol* 2013; 12(3): 204–209. doi: 10.1111/jocd.12044.
- Paolo F, Nefer F, Paola P, Nicolò S. Periorbital area rejuvenation using carbon dioxide therapy. *J Cosmet Dermatol* 2012; 11(3): 223–228. doi: 10.1111/j.1473-2165.2012.00633.x.
- Kotz S, Balakrishnan N, Read CB, Vidakovic B, Johnson NL. *Encyclopedia of statistical sciences*. 2nd ed. Hoboken, NJ: Wiley-Interscience; 2006.
- Kirkpatrick LA, Feeney BC. *A simple guide to IBM SPSS statistics for version 20.0*. Student ed. Belmont, California: Wadsworth, Cengage Learning; 2013.
- Mashood AA. Treatment of hyperpigmentation disorders. *Journal of Pakistan Association of Dermatologists* 2006; 16: 65–68.
- Gendler EC. Treatment of periorbital hyperpigmentation. *Aesthet Surg J* 2005; 25: 618–624. doi: 10.1016/j.asj.2005.09.018.
- Slavin JW. Considerations in alpha hydroxy acid peels. *Clin Plast Surg* 1998; 25(1): 45–52.
- Nach R, Zandifar H, Gupta R, Hamilton JS. Subcutaneous carboxytherapy injection for aesthetic improvement of scars. *Ear Nose Throat J* 2010; 89(2): 64–66.
- Chun EY, Lee JB, Lee KH. Focal trichloroacetic acid peel method for benign pigmented lesions in dark-skinned patients. *Dermatol Surg* 2004; 30(4): 512–516. doi: 10.1111/j.1524-4725.2004.30166.x.
- Usuki A, Ohashi A, Sato H, Ochiai Y, Ichihashi M, *et al.* The inhibitory effect of glycolic acid and lactic acid on melanin synthesis in melanoma cells. *Exp Dermatol* 2003; 12(Suppl 2): 43–50. doi: 10.1034/j.1600-0625.12.s2.7.x.
- Sachdeva S. Lactic acid peeling in superficial acne scarring in Indian skin. *J Cosmet Dermatol* 2010; 9(3): 246–248. doi: 10.1111/j.1473-2165.2010.00513.x.
- Sharquie KE, Al-Tikreety MM, Al-Mashhadani SA. Lactic acid chemical peels as a new therapeutic modality in melasma in comparison to Jessner’s solution chemical peels. *Dermatol Sur* 2006; 32(12): 1429–1436. doi: 10.1111/j.1524-4725.2006.32352.x.
- Varlato V, Manzo G, Mugnaini F, Bisacci C, Fiorucci P, *et al.* Carboxytherapy: Effects on microcirculation and its use in the treatment of severe lymphedema. *Acta Phlebolog* 2007; 8: 1–13.
- Zenker S. Carboxytherapy: Carbon dioxide injections in aesthetic medicine. *Prime Europe* 2012; 2(1): 42–50.
- Ferreira JCT, Haddad A, Tavares SAN. Increase in collagen turnover induced by intradermal injection of carbon dioxide in rats. *J Drugs Dermatol* 2008; 7(3): 201–206.