

## PERSPECTIVES

## Guidelines for removing permanent makeup

C. Bettina Rümmelein

Dr. Rümmelein AG – House of Skin & Laser Medicine, Grüstrasse 55, Kilchberg, Zürich, Switzerland

**Abstract:** Permanent makeup (PMU) is a frequently implemented cosmetic procedure performed by beauticians. From a technical point, PMU is considered a facial tattoo. Failed procedures or a change of mind can lead to the desire for removal. The purpose of this retrospective evaluation of patients who came to the clinic with the desire to remove PMU between 2011 and 2015 was to explore the problems, side effects, and results in order to define treatment guidelines for other doctors. We evaluated 87 individual cases in total. In treatable cases, *i.e.* 52 out of the 87 cases, laser treatments were performed using a nanosecond Q-switched neodymium-doped yttrium aluminium garnet (Nd:YAG) laser. It takes between 1-12 treatments to remove the PMU. In three cases, the colour of the PMU could not be removed by laser and remained after the treatment. In two cases, laser treatment had to be terminated due our changes towards the green-blue spectrum. Before PMU removal, laser test shots are urgently recommended as unforeseeable colour changes can cause severe aesthetically unpleasant results. Covered up PMU (skin colour) is particularly susceptible to changes in colour. Heat-induced shrinking of the eye area can cause an ectropium. Surgical solutions also have to be taken into consideration. The use of proper eye protection with intraocular eye shields is mandatory. This article is an attempt to set up some guidelines for the treatment of PMU removal.

**Keywords:** Permanent makeup; PMU; tattoo; Q-switched laser; colour removal; doctor; aesthetician

**Citation:** Rümmelein CB. Guidelines for removing permanent makeup. *J Surg Dermatol* 2020; 5(1): 49; <http://dx.doi.org/10.18282/jsd.v1.i3.49>.

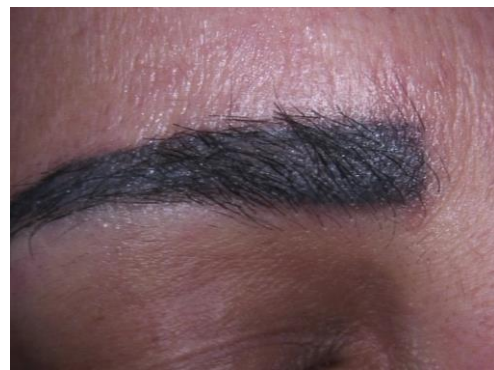Correspondence to: C. Bettina Rümmelein, Dr. Rümmelein AG – House of Skin & Laser Medicine, Grüstrasse 55, 8802 Kilchberg, Zürich, Switzerland; [b.ruemmelein@dr-ruemmelein.ch](mailto:b.ruemmelein@dr-ruemmelein.ch)

**Received:** 26<sup>th</sup> August 2019; **Accepted:** 13<sup>th</sup> October 2019; **Published Online:** 4<sup>th</sup> November 2019

### Introduction

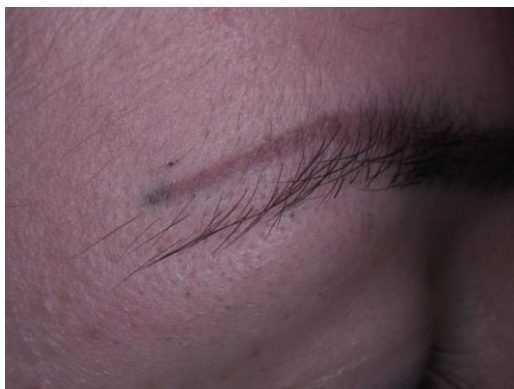Similar to conventional tattoos, cosmetic tattoos called permanent makeups (PMUs) are growing more and more popular. Permanent coloration of the eyelids, eyebrows, and lip outline has been performed with increasing frequency in recent years<sup>[1]</sup>. In contrast to other tattoos, PMUs are not meant to stay for a lifetime but it will vanish after three to five years. To achieve this effect, the colour is not inserted as deep as it is in the case of a conventional tattoo. Aside from aesthetic reasons, PMUs might be used together with reconstructive surgery, for example after a mammilla reconstruction or due to medical issues like alopecia areata totalis. The biggest risk concerning PMU is human failure concerning the

wrong colour choice, site, shape, or a procedural mistake (**Figures 1 and 2**).



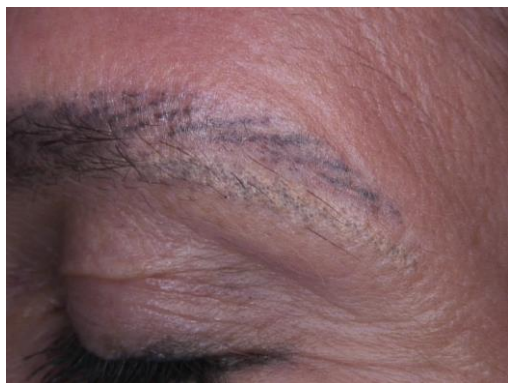**Figure 1.** Wrong shape, too dark

Copyright © 2020 Rümmelein CB. This is an Open Access article distributed under the terms of the Creative Commons Attribution-NonCommercial 4.0 International License (<http://creativecommons.org/licenses/by-nc/4.0/>), permitting all non-commercial use, distribution, and reproduction in any medium, provided the original work is properly cited.

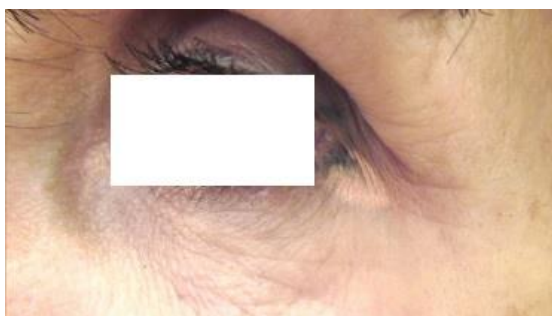


**Figure 2.** Wrong site, colour change

Most of the time, patients in this situation trustfully consult their aesthetician, who offers a skin-coloured cover-up tattoo which is placed right over the failed PMU tattoo. Although this perceived solution sounds very easy, it rarely leads to satisfying results as it often looks unnatural in addition to not fully covering up the original tattoo. Since it cannot adjust to the tanning of the skin, it subsequently becomes very visible during summer. Therefore, an aesthetician should not attempt to cover a tattoo. One should consult a doctor and work out a solution with a dermatologist who specialises in laser medicine (Figures 3 and 4).

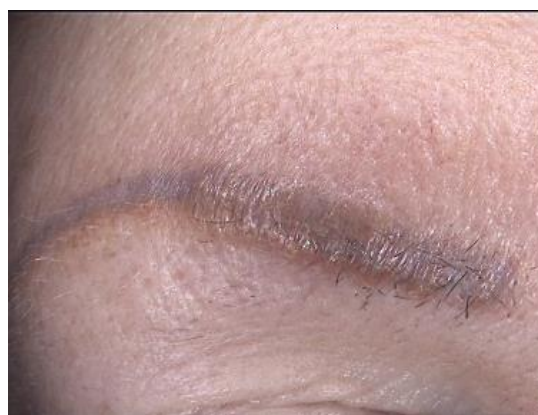

**Figure 3.** Misplaced skin-coloured cover-up



**Figure 4.** Covered-up PMU

Aside from potential aesthetic issues, PMU also carries along a certain risk of medical complications, as does every tattoo. The risk of infections, wound healing complications, keloids, and hypertrophic scars can never be completely eliminated. In very rare cases, eyelid necrosis or ectropion can occur. Lastly, even the inserted colour can lead to negative reactions such as granulomas or allergic reactions (Figure 5).



**Figure 5.** Granuloma after PMU treatment

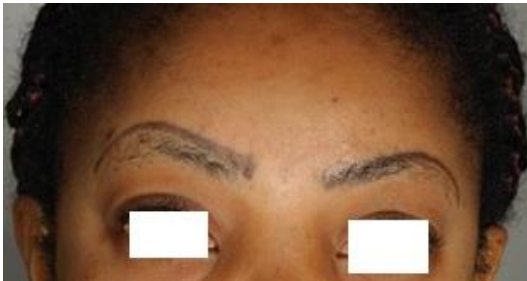Nowadays, tattoos are performed with an electric tattoo gun, which inserts different colourants into the skin. In the past, these colourants used to be inorganic pigments, but these days it is usually made of synthetic organic pigments. Coloured azo pigments are often used for reds and yellows, while polycyclic pigments are used for blues, greens, and violets. Normally, the colours contain metal ions.

Professional tattoo artists order their colours from different producers all over the world. Some of those colours are not entirely pure or the ingredients are not clearly stated. Hence, it is of no surprise that a lot of consumers do not even know what exactly is getting injected under their skin, which automatically poses a threat to their health. The Swiss Federal Institute of Health conducted an investigation of 60 different colourants in 2013, which resulted in 55% of it being prohibited<sup>[2]</sup>.

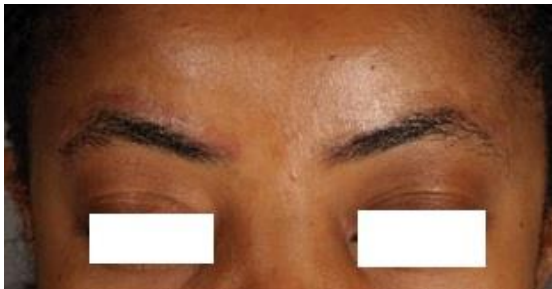Since 2006, tattoo colourants are regulated by the food law act with statutory chemical and microbiologic quality standards<sup>[3]</sup>. However, in the EU, there are countries that do not have any rules or regulations and if they do, they differ in each country.

The method of choice for removing intradermal pigment is treatment with a Q-switched neodymium-doped yttrium aluminium garnet (Nd:YAG) laser<sup>[4,5]</sup>. Q-switched laser utilises the principle of selective photothermolysis, whereby the wavelength is chosen in accordance with the target chromophore and the duration

of the pulse has to be briefer than the thermal relaxation time. If these guidelines are followed properly, an unspecific heating of the surrounding skin can be avoided<sup>[6]</sup> leading to scarring in less than 5% of cases. In the case of multi-coloured PMUs, different wavelengths have to be combined (Figures 6 and 7).



**Figure 6.** Wrong sited PMU before treatment (Source: University Hospital Zürich)



**Figure 7.** After treatment (Source: University Hospital Zürich)

The skin depth that the laser light is able to penetrate depends on the wavelength and the size of the spot on the laser. Longer wavelengths and bigger spots lead to an increased penetration depth.

When the light of the laser enters the skin and meets the colour, it shatters the pigments to small fragments, which are then removed either by macrophages through phagocytosis or via the lymphatic system<sup>[7]</sup>. A typical

reaction observed immediately after treatment is instant whitening of the skin which is caused by the release of gas while heating the pigment.

## Materials and methods

In the time period between 2011 and 2015, 87 patients requested for the removal of their PMUs in our clinic. Out of the 87, 52 were judged as treatable while the remaining 35 were excluded from treatment. The reasons for the exclusion were non-treatable colours, unrealistic expectations, and patients' decision not to undergo treatment because of potential side effects.

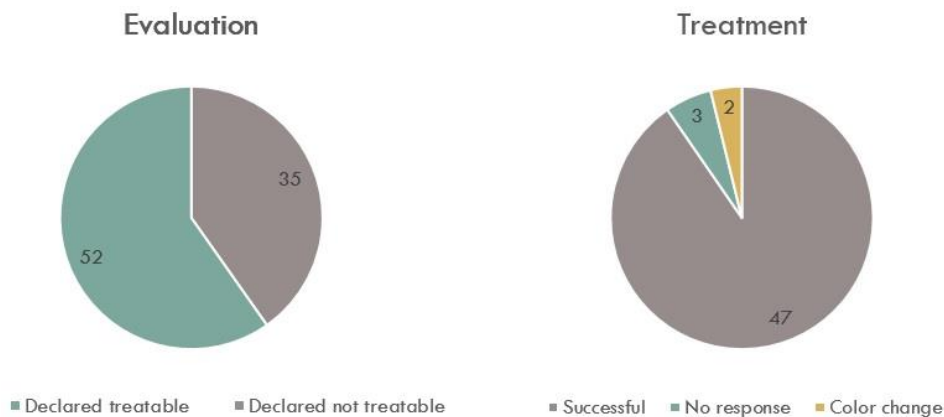
In each case, treatment was performed with a Nd: YAG nanosecond laser. Appropriate eye protection is crucial; hence, metal protection goggles, specialised laser protection eye-stickers, or intraocular eye shields were used in order to ensure sufficient patient safety.

The procedure began with an 8-mm spot at an energy density of 1–1.5 J/cm<sup>2</sup>, depending on the reaction to the colour. The lowest possible energy to perform immediate whitening was used. During treatment, air cooling was applied. After 20 minutes, a second treatment was performed under the exact same conditions.

## Results

In 47 of the 52 cases, PMU was successfully removed after 1–12 treatment sessions. In three cases, the colour remained after laser treatments and in two other cases, the colour of the tattoo started to change into a bluish green colour, which led to the treatment being put on hold and ultimately terminated. In those cases, the colour had to be surgically removed.

In summary, out of a total of 87 patients, 52 were eventually treated and 47 of them have had their PMUs completely removed. No cases of scarring or unwanted hair loss were observed (Figure 8).



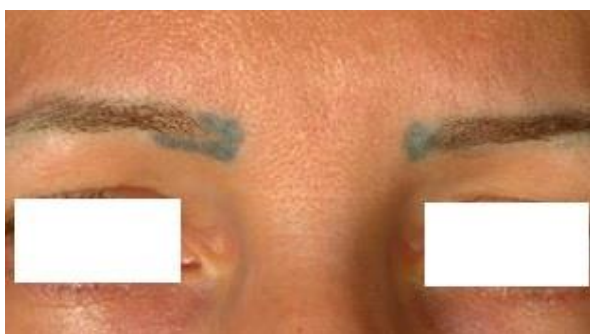**Figure 8.** PMU removal statistics

## Discussion

The major risk of using laser to remove PMUs is a paradoxical darkening of the colour, which is unfortunately the exact opposite of what the attending doctor is trying to accomplish. It seems as if colours containing bright pigments (often skin colour) are most vulnerable to such colour darkening<sup>[8]</sup>. Although this strange reaction has yet to be explored in detail, it is rather safe to assume that it has something to do with the different states of iron and titanium oxidation, *e.g.*, as  $\text{Fe}^{2+}$  (ferruginous colour) oxidises into  $\text{Fe}^{3+}$  (black)<sup>[9]</sup>. In most cases, those resulting colours cannot be removed by lasers, which means that surgical methods have to be considered.

Another risk is trying too hard to remove the PMU, instead of just accepting that the skin is not responding to the treatment. This often results in fibrosis and hypopigmentation, especially after Q-switched ruby-laser treatments. It can also lead to hyperpigmentation in the case of darker skin types. In these cases, a Nd:YAG-laser is recommended as it is safer to use on the epidermis due to its long wavelength. If signs of scarring occur, the actual treatment with the Q-switched laser can be combined by using a fractional  $\text{CO}_2$ -laser which seems to reduce those side effects<sup>[10]</sup>.

To avoid such complications, a test-treatment should always be performed on a hidden area of the skin in order to observe how the skin and colour react to the laser. Patients should also be informed that this treatment will take more than a few sessions and that they have to live with a work in progress for some time (**Figure 9**).



**Figure 9.** Discolouration of a skin-coloured PMU after laser treatment

## Conclusion

While it is very easy to have a PMU tattoo done, removing it poses a significantly bigger challenge, which in turn leads to a relatively high number of complications due to unprofessional methods of removal. Failed

removal attempts—the cases wherein a change in colour occurs—can even exacerbate the problem, leaving excision as the last resort procedure. The major problem concerning tattoo colourants are its ingredients, which are not regulated by law in many countries<sup>[11]</sup>.

For pigment removal, the method of choice is a Q-switched laser. Treatments should only be performed by qualified doctors in order to avoid eye damage and side effects such as scarring. Our numbers suggest that if applied correctly, the Q-switched laser can achieve excellent results in a majority of cases. With tattoos that consist of colours other than black, a laser with the correct wavelength has to be chosen in order to remove it; hence a multi-coloured tattoo requires the combination of different laser types (**Table 1**)<sup>[12]</sup>.

**Table 1.** Which laser for which colour?

Laser	Black	Blue	Green	Red
Alexandrite 755 nm	X	X	XX	
Ruby 694 nm	X	X	X	
Nd:YAG 1064 nm	X	X		
Nd:YAG 532 nm				X

Treatment of coloured tattoos can be tricky, which is why there should also be a test shot prior to every laser treatment in order to test the reaction of the colour. This is best performed on a small, hidden area of the skin where a potential colour change cannot be seen right away or the area can be excised in case of a bad reaction.

If these guidelines are followed closely, Q-switched laser can be considered the gold-standard for PMU removal when the laser treatment is performed by a qualified doctor. Unfortunately, patients and even aestheticians often lack relevant information. Federal authorities should earnestly consider patient safety and enforce adequate regulations.

Take-home messages:

- Q-switched laser is the method of choice for removing PMUs.
- Always consult a doctor with a certificate of competence for laser treatments in case of a failed PMU.
- Always perform a test shot small enough to be excised in case of a colour change.
- Eye protection with metallic safety goggles or, if needed, even disposable eye shield stickers are mandatory. When applied on the eyelid, special intraocular eye shields have to be used.



## Author Contributions

Dr. Rümmelein presented this topic at the IMCAS World Congress in January 2016 and has now transcribed her spoken words into this article.

## Acknowledgements

Fabio Donisi, a student of journalism and communication at the University of Zürich, worked on the visualization of the subjects. He also took charge of the statistics and communicated with the publisher on Dr. Rümmelein's behalf.

## Conflict of interest

The authors declare no potential conflict of interest with respect to the research, authorship, and/or publication of this article.

## References

---

1. Worp J, Boonstra A, Coutinho RA, van den Hoek JA. Tattooing, permanent makeup and piercing in Amsterdam; guidelines, legislation and monitoring. *Euro Surveill* 2006; 11(1): 34–36.
2. Hauri U. Tinten für permanent makeup (PMU) und zur tätowierung / Organische pigmente, konservierungsmittel, verunreinigungen (German) [Ink for permanent makeup (PMU) and tattoo / Organic pigments, preservatives, contaminants][Internet]. Department of Health, Canton Basel-Stadt; 2013 [cited 2016 Feb 8]. Available from: [http://www.kantonslabor.bs.ch/dms/kantonslabor/download/berichte/berichte-2012/PMU\\_Tattoo\\_2012.pdf](http://www.kantonslabor.bs.ch/dms/kantonslabor/download/berichte/berichte-2012/PMU_Tattoo_2012.pdf)
3. The Committee of Ministers. Resolution ResAP (2008) 1 on requirements and criteria for the safety of tattoos and permanent make-up (superseding Resolution ResAP (2003) 2 on tattoos and permanent make-up)[Internet]. 1018<sup>th</sup> meeting of the Ministers' Deputies, Strasbourg, The Council of Europe; 2008 [cited 2016 Feb 8]. Available from: [https://search.coe.int/cm/Pages/result\\_details.aspx?ObjectID=09000016805d3dc4](https://search.coe.int/cm/Pages/result_details.aspx?ObjectID=09000016805d3dc4)
4. Prinz BM, Vavricka SR, Graf P, Burg G, Dummer R. Efficacy of laser treatment of tattoos using lasers emitting wavelengths of 532 nm, 755 nm and 1064 nm. *Brit J Dermatol* 2004; 150(2): 245–251. doi: 10.1111/j.1365-2133.2004.05658.x.
5. Schönewolf NL, Rümmelein B, Bogdan-Allemann I, Dummer R. Tätowierungen und wie man sie wieder los wird (German) [Tattoos and how to remove it]. *Schweiz Med Forum* 2010; 10(19–20): 340–343.
6. Anderson RR, Margolis RJ, Watanabe S, Flotte T, Hruza GJ, *et al.* Selective photothermolysis of cutaneous pigmentation by Q-switched Nd: YAG laser pulses at 1064, 532, 355 nm. *J Invest Dermatol* 1989; 93(1): 28–32.
7. Herd RM, Alora MB, Smoller B, Arndt KA, Dover JS. A clinical and histologic prospective controlled comparative study of the picosecond titanium: Sapphire (795 nm) laser versus the Q-switched alexandrite (752 nm) laser for removing tattoo pigment. *J Amer Acad Dermatol* 1999; 40(4): 603–606.
8. Mao JC, DeJoseph LM. Latest innovations for tattoo and permanent makeup removal. *Facial Plast Surg Clin North Am* 2012; 20(2): 125–134. doi: 10.1016/j.fsc.2012.02.009.
9. Lee CN, Bae EY, Park JG, Lim SH. Permanent makeup removal using Q-switched Nd:YAG laser. *Clin Exp Dermatol* 2009; 34(8): 125–134. doi: 10.1111/j.1365-2230.2009.03268.x.
10. Weiss ET, Chapas A, Brightman L, Hale EK, Karen JK, *et al.* Successful treatment of atrophic postoperative and traumatic scarring with carbon dioxide ablative fractional resurfacing: Quantitative volumetric scar improvement. *Arch Dermatol* 2010; 146(2): 133–140. doi: 10.1001/archdermatol.2009.358.
11. Kluger N, Koljonen V. Tattoos, inks, and cancer. *Lancet Oncol* 2012; 13(4): e161–e168. doi: 10.1016/S1470-2045(11)70340-0.
12. Choudhary S, Elsaie ML, Leiva A, Nouri K. Lasers for tattoo removal: A review. *Lasers Med Sci* 2010; 25(5): 619–627. doi: 10.1007/s10103-010-0800-2.